



## Gastroesophageal Surgery Case

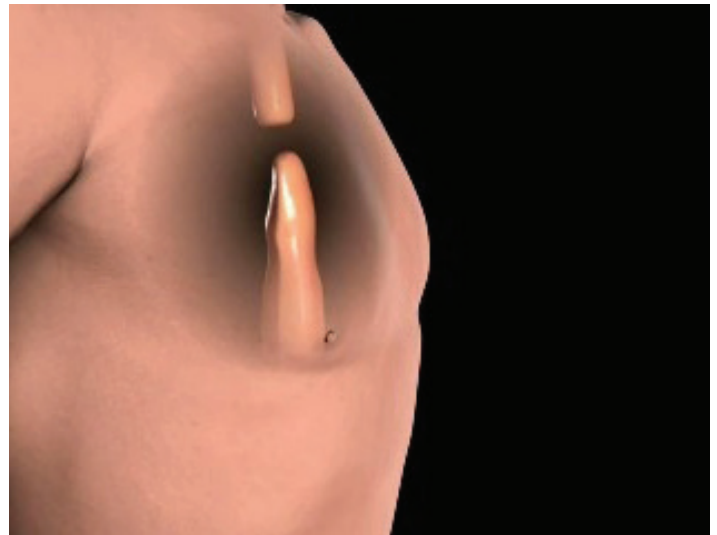### A 69-Year-Old Man with Esophageal Tumor

CHRISTOPHER MORSE, MD  
*Massachusetts General Hospital*

#### PRESENTATION OF CASE

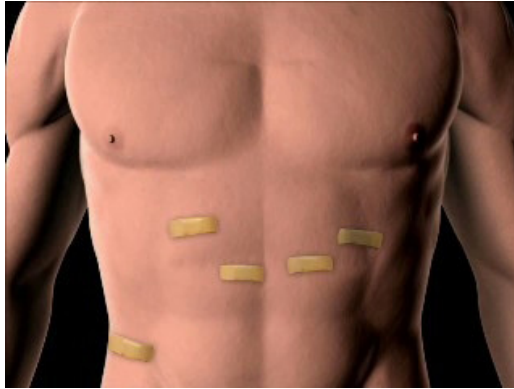
A 69-year-old male with minimal past medical history beyond hypertension began having difficulty with swallowing, primarily solid food. His primary care physician ordered a barium swallow that demonstrated an irregularity in the distal esophagus. An upper endoscopy revealed a mass in the esophagus, and biopsies returned with an esophageal adenocarcinoma. The patient was staged with an endoscopic ultrasound examination of the tumor and PET/CT scan, and underwent chemotherapy and radiation treatment for six weeks prior to surgical resection. At six weeks following the completion of his chemoradiotherapy, he underwent a minimally invasive esophagectomy (MIE). Postoperatively, he spent one day in the ICU before being transferred to the regular hospital floor. He was started on an advancing diet and discharged to home on postoperative day seven.

Esophagectomy remains a mainstay in the treatment of early or locally advanced esophageal cancer and typically involves removing a portion of the esophagus and reconstructing it with the stomach (Figure 1). Historically, esophagectomy has been associated with high rates of morbidity and mortality. In 2002, an analysis of the national

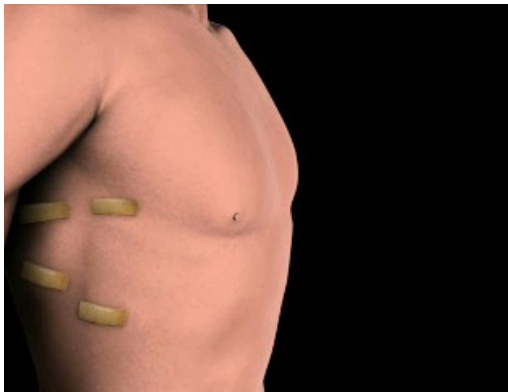

**FIGURE 1.** With an esophagectomy, the tumor is resected and the stomach is used to reconstruct the esophagus that has been removed.

Medicare claims database and the Nationwide Inpatient Sample revealed mortality rates for esophagectomy ranging between 8.1% and 23.1% across the United States and showed an association with hospital volume in that lower-volume hospitals had higher rates of complication<sup>1</sup>.



**FIGURE 2.** Prior to resecting the esophagus, the stomach is mobilized laparoscopically through five small incisions.



**FIGURE 3.** With the stomach mobilized, the patient is turned and the esophagus is resected and removed through four small incisions in the chest, avoiding spreading of the ribs.

Given these high rates of postoperative morbidity and mortality, minimally invasive techniques to esophagectomy are gaining popularity in an attempt to improve outcomes. MIE is performed with small incisions using laparoscopic and thoracoscopic skills (Figures 2-3). One of the largest series to date reported postoperative major morbidity ranging between 2% and 5% for specific

complications after MIE, while mortality was reported at an impressively low 0.9%<sup>2</sup>. Although these are the results of a high-volume, highly experienced center, they support the pursuit of a minimally invasive technique as the routine approach to esophagectomy. However, the learning curve for the operation is rather steep.

At Massachusetts General Hospital, we have developed an extensive experience with a minimally invasive approach to esophagectomy and have concentrated on several key aspects. We wanted to ensure that the procedure was initially safe as we grew our experience. Publishing this in 2008, we also showed a low rate of complication in both patients who did and did not receive chemoradiotherapy prior to surgery<sup>3,4</sup>. As our experience continued to grow, we compared our minimally invasive experience with esophagectomy to our open surgical experience. This report was presented at the European Association for Cardiothoracic Surgery meeting in Portugal in 2011 and demonstrated a significant drop (3% MIE to 45% open cases) in pulmonary complications in patients receiving a minimally invasive approach to esophagectomy. Additionally, there was a shorter length of stay and similar oncologic outcomes<sup>5</sup>.

In summary, minimally invasive esophagectomy should only be performed at high volume centers by high volume providers with excellent laparoscopic and thoracoscopic skills. However, when done well, a minimally invasive approach appears to offer an advantage over traditional open approaches as demonstrated at Mass General and other centers.



---

## REFERENCES

1. Birkmeyer JD, Stewers AE, Finlayson EV, Stukel TA, Lucas FL, Batista I, et al. Hospital volume and surgical mortality in the United States. *N Engl J Med* 2002;346(15):1128-37.
2. Luketich JD, Pennathur A, Awais O, Levy RM, Keeley S, Shende M, et al. Outcomes after minimally invasive esophagectomy: review of over 1000 patients. *Ann Surg* 2012;256(1):95-103
3. Tapias LF, Morse CR. Minimally invasive Ivor Lewis esophagectomy after induction therapy yields similar early outcomes to surgery alone. *Innovations (Phila)* 2011;6(5):331-6
4. Tapias LF, Morse CR. A preliminary experience with minimally invasive Ivor Lewis esophagectomy. *Dis Esophagus* 2008;25(5):449-55.
5. Sihag S, Wright CD, Wain JC, Gaissert HA, Lanuti M, Allan JS, Morse CR. Comparison of perioperative outcomes following open versus minimally invasive Ivor Lewis esophagectomy at a single, high-volume centre. *Eur J Cardiothorac Surg* 2012;42(3):430-7