

Why is imaging research important for ALS?

Brain scans using state-of-the-art imaging techniques may deepen our understanding of mitochondrial abnormalities and neuroinflammation in ALS and other motor neuron diseases. It could help us understand differences in how individuals may respond to experimental treatments targeting inflammation in clinical trials. If successful, this research could improve efficiency of trial designs and improve probability of successes of future ALS clinical trials targeting neuroinflammation.

How is inflammation captured in imaging?

Inflammation and mitochondrial abnormalities will be measured in different brain regions using a PET dye (tracer) called PBR28 tracer. PBR28 injected via IV (intravenously), reaches the brain by blood and attaches to inflammatory cells in the brain. Using a sophisticated combined (2 in 1) scanner at MGH, which uses both MRI and PET imaging, a single high resolution brain scan will help visualize inflammation areas accurately.

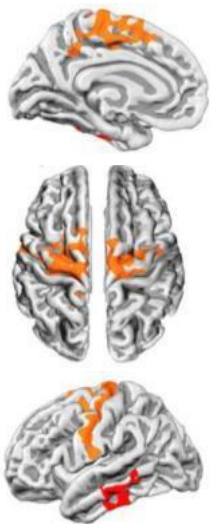

Figure above is an example of a complete brain scan and highlights inflammation in ALS patients.

Connect to ALS Research at the Healey Center!

Sign up for the MGH ALS Link:



<https://lp.constantcontactpages.com/su/saTzwlp/ALSLink>

View currently enrolling ALS trials:



<https://www.massgeneral.org/neurology/als/research/als-clinical-trials>

For more information about this study:

Contact the research coordinator(s) listed for the study or Judi Carey, Research Access Nurse, at jcarey8@partners.org or 617-724-8995



MASSACHUSETTS
GENERAL HOSPITAL

NEUROLOGICAL CLINICAL RESEARCH INSTITUTE



Healey Center

Sean M. Healey & AMG Center
for ALS at Mass General

Currently Enrolling Imaging Biomarker Study



Updated: November 2021

Study of Neuroinflammation (PBR28) Imaging

+ALS (<18 month since onset of weakness)

+Primary Lateral Sclerosis

+Hereditary Spastic Paraplegia

+Known carriers of ALS genes

Trial Name: Glial Activation Measured by PBR28-PET in People with Neurodegenerative Diseases

The purpose of the study is to learn about inflammation in the brains of people with early ALS (<18 months since weakness onset) & Hereditary Spastic Paraplegia (HSP) using combined Magnetic Resonance Imaging (MRI) and Positron Emission Tomography (PET). Previous research has shown increased brain inflammation in ALS patients, and our study aims to further understand this relationship and to investigate inflammation in other neurodegenerative diseases such as HSP.

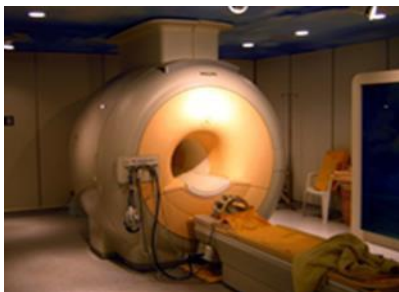Participation requires 1-2 visits at MGH over a three month period. Participants must be 18-80 years old, medically safe to undergo an MRI scan and able to safely lie flat for 90 minutes.

For more information or to determine your eligibility, please contact the coordinators:

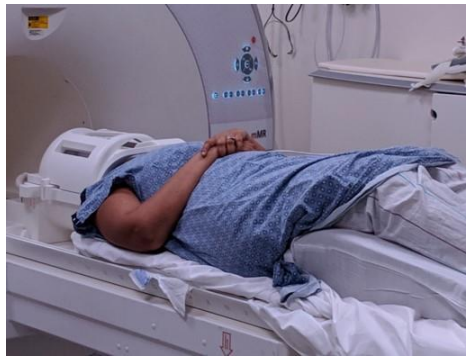Principal Investigator: Suma Babu, MD, MPH

Sponsors: Neurodegenerative Disease Pilot Study Grant, K23 NS 083715, Evan and Arlene Yegelwel Endowed Fund for Primary Lateral Sclerosis Research and Care, PET Imaging of inflammation and epigenetics in ALS (ALS ONE), Muscular Dystrophy Association, Sundry

Enrollment Contacts: Austin Lewis 617-724-7928 alewis29@mg.harvard.edu or Mackenzie Keegan 617-643-6252 mkeegan@mg.harvard.edu



Example of MR-Pet Scanner



Picture of person at opening of MRI/PET scanner

What to expect the day of the MRI/PET scan?

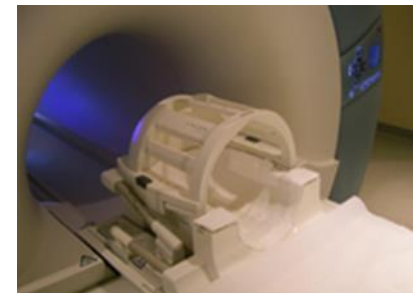
The participant will meet with our study team to discuss the study in detail. We will complete study outcomes including a neurological exam, strength testing, cognitive testing, MR-PET safety questionnaires, blood collection and optional lumbar puncture (early ALS only). Next, either on the same day or a different day, a study coordinator will accompany the participant to the MGH Martinos Center for Biomedical Imaging Center in Charlestown, MA. and will stay with the participant for the entire visit. Here, the IV and optional arterial line (early ALS only) will be placed by a licensed professional. Shortly after, the 90-minute MR-PET scan will begin. Once the scan is complete, there will be a short observation period for participants that had an arterial line, and the participant is free to leave. The entire visit lasts ~6 hours.

Am I eligible to participate in this imaging study?

If you are diagnosed with ALS or HSP or carry an ALS causing gene, you may be eligible to participate. We are enrolling ALS participants who are in the first 18 months since weakness onset, to understand inflammation in early stages of ALS.

Are there risks associated with the MRI/PET scan?

This research has grown over the past 10+ years. Until date, PBR28 dye has been administered in 200+ brain and spinal cord scans of ALS participants. PBR28 dye is safe and well tolerated and there are no reported PBR28 dye related adverse events to date in ALS. Some of the risks of participating in the study include participant discomfort due to lying flat in the scanner tube for 90 minutes, small risk of radiation exposure due to the dye, and risk of pain/bruising at the IV and arterial-line sites used for dye injection and blood PBR28 dye concentration measurements during the scan. ALS Participants may additionally opt-in to participate in optional spinal taps (Lumbar Puncture) to compare imaging with spinal fluid inflammatory biomarkers in ALS. Such participants may face standard risks of spinal tap procedures including low back pain, bruising at LP site or headaches temporarily.



Example of head coil worn during scan