

Nonradioactive Magnetic Marker for Breast Tumor Localization

- Wire-guided localization, long the gold standard for preoperative localization of breast tumors, has a number of inherent limitations.
- Radioguided and radioactive seed localization were introduced as alternatives to wire-guided localization, but these techniques also have disadvantages.
- In a study published this month, Mass General Hospital researchers assessed the feasibility and effectiveness of a noninvasive, nonradioactive option: magnetic marker localization.

Breast cancer death rates in the United States have been steadily declining over the past few decades, in part due to earlier detection by radiologists. The decline can be attributed to a greater emphasis on breast cancer screening in primary care, advances in breast imaging technology and heightened patient awareness of the need for and availability of screening. As cancers are detected earlier, a greater proportion are non-palpable at the time of diagnosis. This otherwise positive effect has implications for localizing tumors prior to surgical excision. In recent years, researchers have been exploring a variety of approaches for localization, including the use of magnetic markers. Massachusetts General Hospital was one of the first institutions to adopt the magnetic marker technology and, to date, has performed more magnetic marker procedures than any other hospital. The approach was recently assessed by a team of investigators at Mass General in an article published in the American Journal of Roentgenology this month.

Wire-guided Localization of Breast Tumors

Historically, surgeons relied on noninvasive, but imprecise, approaches for localization of breast tumors, including the use of ink markings on the skin. In recent decades, noninvasive techniques have been replaced by more invasive accurate procedures, particularly due to the higher proportion of non-palpable malignancies. Currently, the gold standard for preoperative localization involves the use of needle-wire assemblies. With this technique, a radiologist inserts the tip of a thin metal wire into or near the tumor. At the time of resection, the surgeon identifies and removes the tissue surrounding the tip under direct visualization.

Wire-guided localization has yielded important improvements in breast cancer surgery, but the technique has several inherent disadvantages. For example, positive margin rates – that is, the occurrence of cancer cells remaining at the edge of the area of resection – can be high. Researchers have reported rates ranging from 14% to 47%. Also, patients must manage a protruding wire from the time of insertion to the time of surgery. Additionally, the wire may break or dislodge during the procedure, leading to less effective localization.

Radioguided and Radioactive Seed Localization of Breast Tumors

In recent years, researchers have explored safe and effective alternatives to wire-guided localization for non-palpable tumors, including radioguided localization and radioactive seed localization. Introduced in 1998, radioguided localization involves injection of a liquid radioactive tracer into the tumor, prior to the procedure, under ultrasound or mammographic guidance. The surgeon uses a gamma ray probe to detect the tracer and guide tumor resection. Radioactive seed localization, first described in the literature in 2001, replaced the tracer with a radio-opaque titanium seed containing Iodine-125.

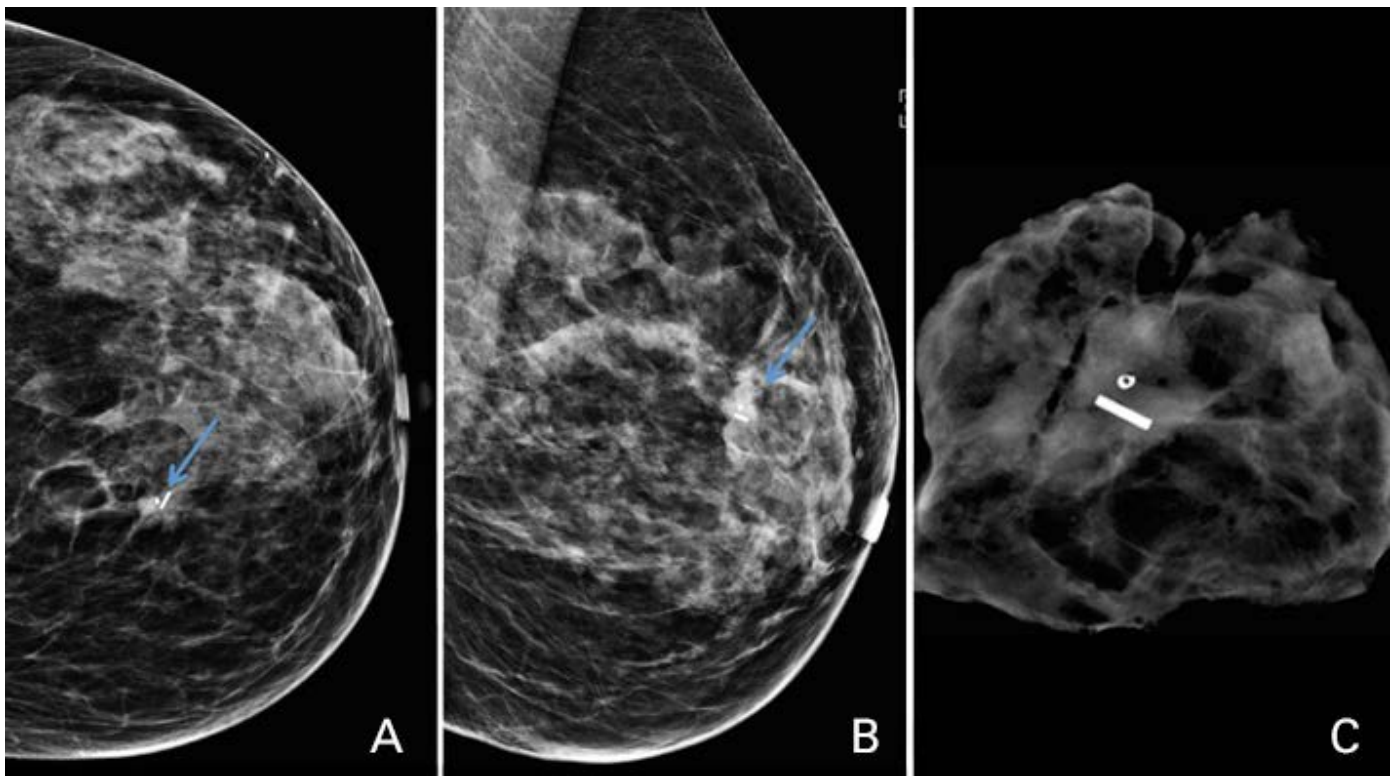


Figure 1. Shown here are images from a magnetic marker localization at Massachusetts General Hospital. A female presented with a screening-detected mass in the left breast at 11 o'clock. The mass was biopsied under ultrasound guidance, with a pathology result of invasive ductal carcinoma, grade 2, ER/PR+, HER2-. The mass was localized under ultrasound guidance with a single magnetic marker. **(A)** Post-localization craniocaudal and **(B)** mediolateral oblique mammographic images demonstrate successful marker placement adjacent to the biopsy clip placed at the time of biopsy. **(C)** Specimen radiograph demonstrates successful retrieval of the mass, biopsy clip and magnetic marker.

Several studies have reported the advantages associated with radioactive seeds, which have become increasingly accepted and used. Compared with wire localizations, radioactive seeds are associated with similar, if not slightly improved, tumor-negative surgical margin rates and re-excision rates. The advantages of wireless localizations include improved scheduling times (with seeds placed before the day of surgery), shorter localization procedure times, improved patient tolerance and reduced costs. There are, however, disadvantages of a radioactive device—specifically, extensive nuclear medicine regulatory requirements associated with both increased costs and greater staffing needs.

For these reasons, researchers have recently been exploring the possibility of nonradioactive wireless localization, including image-guided localization systems with nonradioactive magnetic markers.

Magnetic Marker Localization of Breast Tumors

Magnetic marker localization uses encased super-paramagnetic iron oxide particles that can be injected into a tumor, similar to radioactive seed insertion. Using a handheld magnetic probe, similar to the gamma probe used with radioactive seed localization, the surgeon is able to detect the magnetic signal once in the operating room. Using magnetic markers for tumor localization has distinct advantages over using radioisotopes. Unlike the extensive regulatory requirements for the use of radioactive seeds, nonradioactive markers do not need such approval. Magnetic markers can therefore be used in facilities where radioactive seed localization is not practical (e.g., in hospitals lacking a nuclear medicine department). Certain nonradioactive markers may be placed weeks or even months before surgery, whereas most radioactive seeds typically are removed within five days after placement.

In a [study reported this month](#) in the American Journal of Roentgenology, a team of researchers at Mass General sought to assess the feasibility and effectiveness of a nonradioactive magnetic marker wireless localization technique. The retrospective review of 188 patients who underwent image-guided localization with 213 magnetic markers examined several outcomes. The authors found that surgeons retrieved all 213 of the markers at the time of excision and that 96.7% of the markers had been placed within 1 cm of the target, suggesting that the technique

offers a promising alternative to wire-guided and radioactive seed localization. Re-excision was required in 21.9% of the cases with malignancy because of positive or close surgical margins. This rate is similar to other nonradioactive wireless techniques and similar or better than the results associated with wire localization systems.

Although magnetic markers can overcome some of the drawbacks of wire localizations, they too are limited. Magnetic markers cost more than wires and radioactive seeds; these costs are in addition to those associated with initial purchase of the probes used in the operating room. However, reducing operating room–related delays associated with wire localizations may result in financial savings, as would eliminating costs associated with nuclear medicine support of radioactive seed programs. Future work will focus on a multifactorial economic analysis, in addition to an assessment of patient satisfaction.

Further Information

For more information about the feasibility and effectiveness of magnetic marker localization for tumor resection in the breast, please contact [Leslie R. Lamb, MD, MS](#), Division of Breast Imaging, Department of Radiology, Massachusetts General Hospital. We would like to thank Dr. Lamb, Manisha Bahl, MD, MPH, and Constance D. Lehman, MD, PhD, for their advice and assistance in preparing this article.

References

Gunn J and McLaughlin S. (2017). *Current Trends in Localization Techniques for Non-palpable Breast Lesions: Making the Invisible Visible*. *Curr Breast Cancer Rep* **9**:165–171.

Lamb LR, Bahl M, Specht MC, et al. (2018). *Evaluation of a Nonradioactive Magnetic Marker Wireless Localization Program*. *AJR Am J Roentgenol* **211**(4): 940-945.

Lovrics PJ, Cornacchi SD, Vora R, et al. (2011). *Systematic review of radioguided surgery for non-palpable breast cancer*. *Eur J Surg Oncol* **37**(5): 388-97.

Schermers B, van der Hage JA, Loo CE, et al. (2017). *Feasibility of magnetic marker localisation for non-palpable breast cancer*. *Breast* **33**:50-56.

©2018 MGH Department of Radiology

Gary Boas, Author
Raul N. Uppot, M.D., Editor

