

Prostatic Artery Embolization (PAE): A Minimally Invasive Alternative for Treatment of Benign Prostatic Hyperplasia

- More than 15 million men in the US experience reduced quality of life due to benign prostatic hyperplasia (BPH) and resulting urinary tract symptoms.
- The current gold standard for treating BPH, transurethral resection of the prostate (TURP), is a surgical procedure associated with a wide range of possible complications.
- Prostate artery embolization (PAE) offers a minimally invasive alternative to TURP for treatment of BPH.
- The safety and efficacy of PAE has been demonstrated for BPH, including in cases with large-volume prostates for which TURP is typically not an option.

Benign prostatic hyperplasia (BPH), also known as prostate gland enlargement, is a common problem affecting more than half of men at age 60 and nearly 90% of men at age 85. Though benign, the condition can lead to serious lower urinary tract symptoms (LUTS), including symptoms related to frequency, urgency, weak stream and nocturia. Urinary tract symptoms attributable to BPH result in impaired quality of life for more than 15 million men in the US alone. The overall cost of care for these men is more than \$3 billion (USD) per year.

In current practice, the surgical procedure transurethral resection of the prostate (TURP) is the gold standard for treating BPH caused by an enlarged prostate, offering reductions of up to 70% in the International Prostate Symptom Score (IPSS). However, TURP can result in complications, including incontinence, urethral strictures, bladder neck contracture and sexual dysfunction. To minimize complications, many providers are turning to prostate artery embolization (PAE), an emerging minimally invasive, endovascular treatment that reduces the size of the prostate by blocking the flow of blood to the gland.

Prostate Artery Embolization Offers Significantly Improved Outcomes

The first planned PAE was performed in 2008 and published in the journal *Cardiovascular Interventional Radiology* in 2010. Since then, researchers have been working to validate the technique by exploring its safety and efficacy, especially with respect to TURP. In a review and meta-analysis of this literature, published in 2019 in the journal *European Radiology*, a team of researchers examined a series of outcomes in studies of PAE treatment of BPH. The primary outcome was mean change in IPSS; the researchers also looked at measures of quality of life, prostate volume, prostate-specific antigen, post-void residual, peak urinary flow, International Index of Erectile Function, complications and technical and clinical success rates. They found, at 12-month follow-up, substantial improvements across the board with a low incidence of complications. The meta-analysis showed a 67% reduction in IPSS, which compared well with 70% for TURP. The rates of clinical and technical success in the studies were 76.3 to 100% and 76.7 to 100%, respectively.

The improvements with PAE appear to hold over time. In 2016, researchers published a report of the medium- and long-term outcomes of PAE, looking at 630 patients with BPH over 6.5 years. Here, they reported clinical success rates of 85.1% at short-term, 81.9% at medium-term and 76.3% at long-term follow-up. Notably, the incidence of recurrence dropped dramatically over time with most of the clinical failures occurring during the short-term follow-up. Combined with low morbidity and absence of urinary incontinence or sexual dysfunction, these results also supported the use of the technique in treating patients.

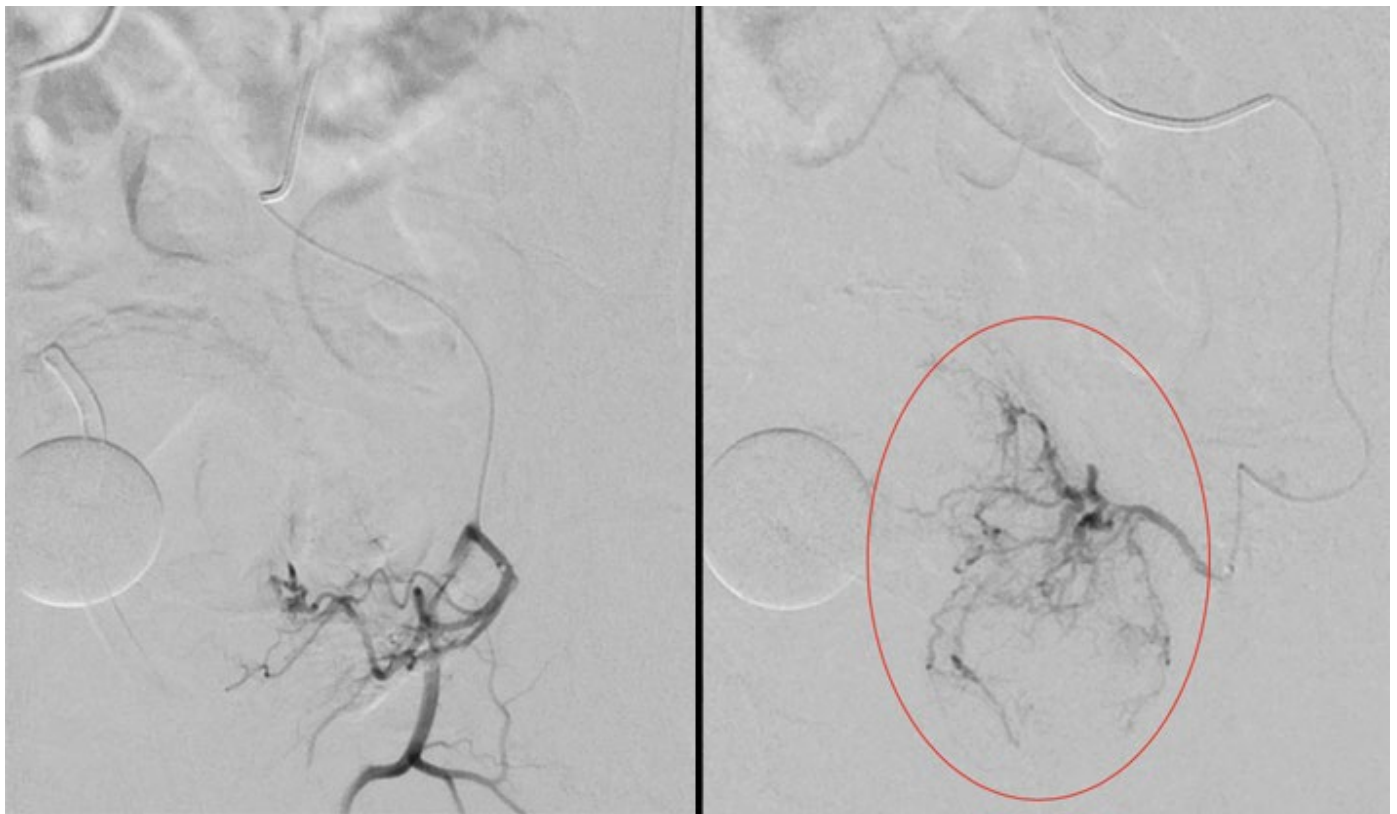


Figure 1. The minimally invasive technique prostate artery embolization helps address lower urinary tract symptoms associated with benign prostatic hyperplasia by blocking the flow of blood to the prostate and thus shrinking the gland. The reduced flow of blood is evident in these digital subtraction angiography (DSA) images acquired before (left) and after (right) the procedure.

Treating Benign Prostatic Hyperplasia in Cases with Large-volume Prostates

PAE can also help in cases where TURP is not an option. In patients with large-volume prostates of 80 mL or more, open prostatectomy replaces TURP as the gold standard treatment. An invasive procedure requiring general anesthetic, open prostatectomy is associated with perioperative blood loss, lengthy catheterization and convalescence and sexual dysfunction among other complications.

In a 2018 issue of the *Journal of Vascular Interventional Radiology*, researchers reported a retrospective review of 93 patients who had undergone PAE with prostate volumes of 80 mL or more. The study followed other reports of PAE in men with large-volume prostates, though many of these studies were based on small, single-center series with limited follow-up. In agreement with previous reports, this 2018 study demonstrated statistically significant and clinically meaningful reductions in IPSS with accompanying improvements in quality of life. The retrospective review also showed that these improvements held true at both 6 months and 12 months after PAE.

Use of Minimally Invasive Procedure Can Help Drive Down Costs

Safety and efficacy are not the only considerations when weighing alternatives to TURP. As hospitals focus increasingly on their spending, researchers are looking more closely into the costs of procedures, especially relative to other treatments available for the same conditions. In a study published earlier this year in the journal *Cardiovascular Interventional Radiology*, a team of investigators examined the costs associated with TURP, PAE and a third procedure used to treat patients with BPH: photoselective vaporization of the prostate (PVP). They found that, while the patient-specific costs were substantially higher with PAE, the total costs of the procedure were in fact significantly lower than with either TURP or PVP.

The researchers attributed this difference to the indirect costs associated with each of the procedures. Both TURP and PVP use considerable perioperative resources and infrastructure, including pre-admission clinics or units, anesthesia, post-anesthesia care units and inpatient wards or surgical short stay units. The only significant indirect

costs associated with PAE stem from the routine post-procedural monitoring performed in the medical imaging day unit—a difference that results in substantially lower total costs. The researchers noted that the typical post-procedure stay in the medical imaging day unit at their institution was 2-4 hours compared to 1-3 days in the surgical short-stay unit.

Further Information

For more information about use of prostate artery embolization for treatment of benign prostatic hyperplasia, please contact [Eric Wehrenberg-Klee, MD](#); Gregory Walker, MD; Kei Yamada, MD; or Zubin Irani, MD, Department of Radiology, Massachusetts General Hospital. We would like to thank Dr. Wehrenberg-Klee as well as Drs. Walker, Yamada and Irani for their advice and assistance in preparing this article.

References

- Bagla S, Smirniotopoulos J, Orlando J, Piechowiak R. (2017). *Cost Analysis of Prostate Artery Embolization (PAE) and Transurethral Resection of the Prostate (TURP) in the Treatment of Benign Prostatic Hyperplasia*. *Cardiovasc Intervent Radiol* 40(11):1694-1697.
- Bhatia S, Sinha VK, Harward S, Gomez C, Kava BR, Parekh DJ. (2018). *Prostate Artery Embolization in Patients with Prostate Volumes of 80 mL or More: A Single-Institution Retrospective Experience of 93 Patients*. *J Vasc Interv Radiol* 29(10):1392-1398.
- Brown AD, Stella SF, Simons ME. (2019). *Minimally Invasive Treatment for Benign Prostatic Hyperplasia: Economic Evaluation from a Standardized Hospital Case Costing System*. *Cardiovasc Intervent Radiol* 42(4):520-527.
- Malling B, Røder MA, Brasso K, Forman J, Taudorf M, Lönn L. (2019). *Prostate artery embolisation for benign prostatic hyperplasia: a systematic review and meta-analysis*. *Eur Radiol* 29(1):287-298.
- Pisco JM, Bilhim T, Pinheiro LC, Fernandes L, Pereira J, Costa NV, et al (2016). *Medium- and Long-Term Outcome of Prostate Artery Embolization for Patients with Benign Prostatic Hyperplasia: Results in 630 Patients*. *J Vasc Interv Radiol* 27(8):1115-22.

©2019 MGH Department of Radiology

Gary Boas, Author
Raul N. Uppot, M.D., Editor

