

# Functional brain mapping of the relaxation response and meditation

Sara W. Lazar,<sup>1,2,CA</sup> George Bush,<sup>1,2</sup> Randy L. Gollub,<sup>1,2</sup> Gregory L. Fricchione,<sup>3,5</sup> Gurucharan Khalsa and Herbert Benson<sup>4,5</sup>

<sup>1</sup>Department of Psychiatry, Harvard Medical School, Massachusetts General Hospital-East, CNY-9, 149 13th Street, Charlestown, MA 02129; <sup>2</sup>NMR Center, MGH-East, CNY-9, Charlestown, MA 02129; <sup>3</sup>Department of Psychiatry, Brigham and Women's Hospital; <sup>4</sup>Department of Medicine, Beth Israel Deaconess Medical Center, Harvard Medical School; <sup>5</sup>Mind/Body Medical Institute, Boston, MA 02115, USA

CA: Corresponding Author and Address

Received 15 February 2000; accepted 5 March 2000

Acknowledgements: Supported by the Mind-Body Medical Institute, Clinical Research Training Grant (5T32MH016259), NIDA 00275, NIMH 01611, NARSAD, The Forrest C. Lattner Foundation, Inc. The authors also wish to thank Terry Campell, Bruce Rosen, Julie Bates, Ary Goldberger, Joe Meitus, Jeff Hausdorf and our intrepid subjects.

Meditation is a conscious mental process that induces a set of integrated physiologic changes termed the relaxation response. Functional magnetic resonance imaging (fMRI) was used to identify and characterize the brain regions that are active during a simple form of meditation. Significant ( $p < 10^{-7}$ ) signal increases were observed in the group-averaged data in the dorsolateral prefrontal and parietal cortices, hippocampus/parahippocampus, temporal lobe, pregenual anterior cingulate

cortex, striatum, and pre- and post-central gyri during meditation. Global fMRI signal decreases were also noted, although these were probably secondary to cardiorespiratory changes that often accompany meditation. The results indicate that the practice of meditation activates neural structures involved in attention and control of the autonomic nervous system. *NeuroReport* 11:1581-1585 © 2000 Lippincott Williams & Wilkins.

**Key words:** fMRI; Meditation; Neuroimaging; Relaxation response; Respiration; Stress

## INTRODUCTION

Meditation (observing the breath and passively ignoring everyday thoughts) is one technique that induces a set of integrated physiological changes termed the relaxation response and is effective as a complementary treatment for many diseases [1-5]. Despite the successful use of relaxation response-based treatments, few studies have addressed the neurobiological underpinnings of meditation.

The practice of meditation induces a hypometabolic state characterized by decreases in many physiological measures [6-8] as well as by changes in EEG pattern [7-9]. These EEG changes are different from those associated with sleep [6-10], and suggest that while subjects are deeply relaxed and have decreased peripheral activity, they are engaged in an active mental state requiring intense neural activity. This is in agreement with subjective reports of experienced meditators [11,12].

Functional neuroimaging techniques offer an opportunity to observe changes in regional brain activity and blood flow during meditation. A recent PET study comparing four different forms of meditation found that the inferior frontal, fusiform, occipital and postcentral gyri all had increased activity during a pooled average of meditative states relative to a control condition [13]. Other studies

have reported increases in cerebral blood flow to frontal cortex during transcendental and yoga meditation practice [14,15], in accordance with reports of increased frontal alpha activity seen with EEG [6,7].

In this study we sought to apply the powerful imaging capabilities of high field strength fMRI to identify foci of activity that are modulated by a very simple form of meditation. Concomitant measures of cardiorespiratory activity were also recorded in two subjects to determine whether changes in these measures could potentially influence the fMRI data. We hypothesized that neural structures that have a role in attention and arousal would be activated during meditation (which requires focusing attention on breathing and repeating a particular phrase), and that the fully developed relaxation response would differ from the early (induction) stage of meditation.

## MATERIALS AND METHODS

**Subjects:** Informed consent was obtained as per Massachusetts General Hospital Human Research Committee guidelines. Five right-handed subjects (four male) aged 22-45 participated. None had a history of psychiatric disease. Each had practiced Kundalini meditation daily for at least 4 years.

**Meditation protocol:** Subjects performed a simple form of Kundalini meditation in which they passively observed their breathing and silently repeated the phrase 'sat nam' during inhalations and 'wahe guru' during exhalations. During the control state they silently generated a random list of animals and did not observe their breathing. Two 12 min meditation epochs were preceded by a 6 min control epoch during each 42 min scan (Fig. 1d). Four subjects underwent two scans during a single session, while the fifth subject was scanned only once. An audio tape of the sound of the scanner was provided to each subject prior to their scan, as well as a written description of the experiment. They were instructed to practice the mantra with the tape until they could comfortably achieve a meditative state, despite the beeping sound of the scanner. On the day of the scan, the subjects were reminded of the experimental design before entering the scanner. During the scans verbal prompts were used to indicate the transition between each epoch.

**Functional MRI data acquisition and analysis** Functional MRI techniques used by the MGH NMR Center were employed, and have been extensively described [16–18]. Sixteen 7 mm gradient echo functional slices (TR=6s, TE=30 ms) were collected using a quadrature head coil in a General Electric 3T scanner. Head stabilization was achieved using either a small plastic bite bar or foam pillow padding.

For group analysis, functional scan data and corresponding anatomical scan data was transformed into Talairach space [19], and then globally normalized and averaged across subjects.

Meditation is a dynamic process that gradually leads to a meditative state. Therefore two analyses were performed in order to characterize regional fMRI responses more completely. The primary analysis contrasted the meditation and control periods in the group-averaged data. Activity during the last 6 min of each meditation period was compared to the 6 min control periods (120 time points total per condition per scan). The second analysis (late *vs* early meditation) compared steady-state meditation (the last 2 min of both meditation periods) with meditation induction (the first 2 min of both meditation periods). An automated region-defining algorithm was used on smoothed Kolmogorov–Smirnov (KS) statistical maps [20,21] (effective resolution of 8.1 mm<sup>2</sup> FWHM). Statistical significance was conservatively defined as  $p < 10^{-7}$  in order to correct for multiple comparisons. For both analyses, regions of interest were defined as clusters of  $\geq 3$  voxels with  $p < 10^{-7}$  in the group averaged data, and significantly activated in at least three subjects.

**Physiological measures:** Heart rate, respiration rate, end-tidal CO<sub>2</sub>, O<sub>2</sub> saturation levels, and ECG measures were recorded throughout each scanning session in two subjects [18].

## RESULTS

**Functional MRI signal increases during meditation:** The primary group analysis compared meditation epochs with control epochs. Significant increases were found during meditation in putamen, midbrain, pregenual anterior cin-

gulate cortex and hippocampal/parahippocampal formation (Fig. 1a; Table 1). Significant activation was also observed in the septum, caudate, amygdala and hypothalamus in at least three subjects. However, these foci lay too close to areas of potential susceptibility artifacts to be accurately localized and quantified, given our scanning parameters, and so they were not included in Table 1.

The second analysis (late *vs* early meditation) identified multiple foci of activation within prefrontal, parietal and temporal cortices, as well as in the precentral and postcentral gyri, and hippocampal/parahippocampal formation (Table 1). Activity was also observed in the amygdala, hypothalamus and septum, but proximity to areas of susceptibility artifacts again precluded inclusion in Table 1.

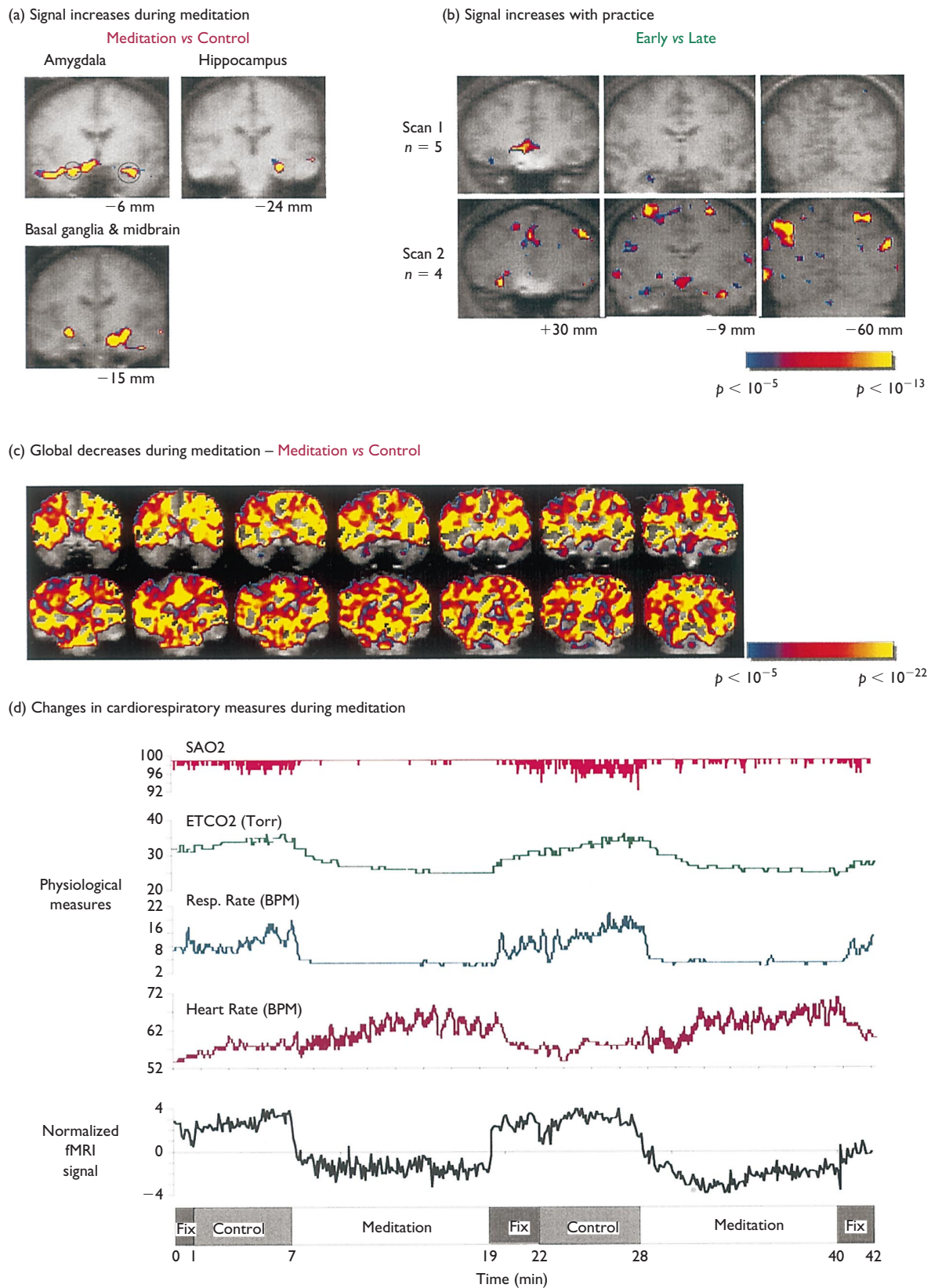
Finally, the first scan from each subject ( $n=5$ ) was averaged together, as were the second scans ( $n=4$ ). The two statistical analyses described above were performed on each data set, and the results were compared. Although there was no consistent difference between the two data sets when the meditation *vs* control contrast is used, the late *vs* early meditation contrast revealed a more robust response during Scan 2 (Table 1; Fig. 1b). The increased pattern of activity was consistent across all measures: during the second scan a greater number of activation foci, a larger percent signal change, and a higher proportion of individuals with significant changes in these regions were observed (Fig. 1b; Table 1).

**Global signal decreases and changes in cardiorespiratory measures:** Two subjects underwent physiological monitoring during scanning. One subject displayed large decreases in respiration rate and end tidal volume CO<sub>2</sub>, and increases in heart rate and blood oxygen saturation levels during meditation, which returned to baseline at the end of the meditation periods (Fig. 1d). This same subject also displayed large global signal decreases in the fMRI signal during the meditation periods (on the order of  $p < 10^{-30}$ ), as did the three subjects whose physiology was not monitored (Fig. 1c). In contrast, the changes in cardiorespiratory function of the other monitored subject were not as pronounced, and this subject did not display large global fMRI signal decreases during meditation.

## DISCUSSION

The data indicate that meditation activates neural structures involved in attention (frontal and parietal cortex) and arousal/autonomic control (pregenual anterior cingulate, amygdala, midbrain and hypothalamus). In addition, significant activation was identified in the putamen, precentral and postcentral gyri and hippocampus/parahippocampus in a majority of subjects, suggesting these structures may also contribute to the meditative state. Extended practice of meditation enhances activation in many structures subserving meditation, as shown in the late *vs* early and scan 1 *vs* scan 2 analyses. Furthermore, these fMRI signal increases were robust: not only were they easily detected in individuals, they were able to overcome what is most likely a strong cardiorespiratory-driven global decrease in BOLD fMRI signal.

The BOLD fMRI technique is by definition sensitive to cardiorespiratory changes, and the fMRI signal was seen to vary with measured physiological changes. Importantly,



**Fig. 1.** Group-averaged pseudocolor KS statistical maps superimposed on a high-resolution coronal anatomical map. The distance in millimeters from the anterior commissure is indicated. (a) Meditation vs control. (b) Late vs early meditation. (c) Global fMRI signal decreases (Subject 4) during meditation as compared to control task. (d) Changes in cardiorespiratory measures and global fMRI signal in Subject 4.

**Table 1.** Activation during meditation.

Anatomical region	Group average					Average run 1			Average run 2			
	Vol (mm <sup>3</sup> )	Coordinates			Max. Vox. p-value	Prop. Indiv.	p-value	% signal change	Prop. Indiv.	p-value	% signal change	Prop. Indiv.
		R/L	A/P	S/I								
Meditation vs control												
Anterior cingulum (BA24a/b)	207	6	33	0	$4 \times 10^{-33}$	80	$9.6 \times 10^{-30}$	3.7	60	$1.1 \times 10^{-18}$	3.1	50
Basal ganglia (putamen)	177	28	-15	-6	$1.4 \times 10^{-26}$	80	$2.4 \times 10^{-21}$	1.4	80	$7.7 \times 10^{-10}$	1.5	50
Midbrain	477	0	-12	-9	$1.0 \times 10^{-31}$	100	$3.4 \times 10^{-12}$	2.8	100	$1.9 \times 10^{-22}$	4.4	100
Midbrain	639	-15	-15	-15	$4.7 \times 10^{-31}$	80	$4.3 \times 10^{-29}$	3.0	60	$1.3 \times 10^{-12}$	2.6	75
Parahippocampal gyrus (BA35)	108	-25	-24	-15	$2.1 \times 10^{-32}$	80	$1.2 \times 10^{-17}$	1.3	80	$9.2 \times 10^{-25}$	1.7	50
Late vs early												
Superior frontal gyrus (BA8)	27	-6	24	50	$1.5 \times 10^{-9}$	60	n.s.	0.2	0	$1.7 \times 10^{-14}$	0.7	75
Middle frontal gyrus (BA9)	27	-40	30	37	$2.4 \times 10^{-8}$	80	n.s.	0.5	0	$1.0 \times 10^{-13}$	2.1	100
Medial frontal gyrus (BA10)	126	12	48	9	$3.0 \times 10^{-12}$	80	n.s.	0.7	60	$2.7 \times 10^{-15}$	0.9	75
Parietal lobule (BA7)	63	-21	-48	53	$7.4 \times 10^{-11}$	60	n.s.	0.2	20	$3.0 \times 10^{-12}$	1.2	75
Superior parietal lobule (BA7)	90	-21	-63	53	$2.4 \times 10^{-8}$	80	n.s.	0.3	20	$1.0 \times 10^{-13}$	1.3	75
Superior parietal lobule (BA7)	54	-31	-57	53	$3.3 \times 10^{-10}$	80	n.s.	0.0	40	$4.2 \times 10^{-16}$	1.9	100
Superior parietal lobule (BA7)	81	-28	-54	43	$2.7 \times 10^{-15}$	60	n.s.	0.3	40	$4.2 \times 10^{-16}$	1.2	75
Superior and inferior parietal lobule (BA7 and 40)	27	40	-60	46	$3.0 \times 10^{-17}$	80	n.s.	0.2	80	$5.6 \times 10^{-13}$	1.6	100
Inferior parietal lobule (BA40)	72	-34	-36	43	$9.2 \times 10^{-8}$	60	n.s.	0.2	20	$1.7 \times 10^{-14}$	0.7	75
Superior temporal gyrus (BA 39)	72	59	-60	28	$3.4 \times 10^{-10}$	80	n.s.	0.8	40	$6.1 \times 10^{-9}$	2.0	75
Middle temporal gyrus (BA 21)	225	59	-57	3	$3.0 \times 10^{-12}$	80	n.s.	0.5	20	$2.7 \times 10^{-15}$	2.2	100
Parahippocampal gyrus (BA 35)	90	-28	-21	-12	$1.5 \times 10^{-9}$	80	n.s.	0.5	60	$6.1 \times 10^{-9}$	1.5	75
Precentral gyrus (BA4)	45	46	-12	53	$7.4 \times 10^{-11}$	60	n.s.	0.4	20	$5.6 \times 10^{-13}$	2.2	75
Postcentral gyrus (BA3)	72	-25	-39	62	$3.0 \times 10^{-12}$	60	n.s.	0.4	0	$6.1 \times 10^{-17}$	1.5	75
Paracentral lobule (BA6)	189	-6	-33	65	$4.2 \times 10^{-16}$	60	n.s.	0.6	20	$4.2 \times 10^{-16}$	1.6	50

Stereotactic coordinates are reported for local maxima meeting threshold criteria (3 contiguous voxels with  $p < 10^{-7}$  in the group-averaged data). Coordinates are expressed in mm from the anterior commissure, with  $x > 0$  corresponding to right hemisphere,  $y > 0$  corresponding to anterior and  $z > 0$  corresponding to superior [19]. Cytoarchitectonic areas are indicated after the named structure in parentheses. The group averaged max. vox. was then used to determine the  $p$ -value and percent signal change from the averaged first ( $n = 5$ ) or second ( $n = 4$ ) scans.

Proportion individuals indicates the percentage of subjects with an activation ( $p < 10^{-7}$ ) within 1 voxel of the activated region as defined in the group averaged scan. Only foci with significant activation in at least three subjects are included in the table.

several observations indicate that changes in cardiorespiratory function were not responsible for the fMRI signal increases measured here. First, the signal increases were regionally specific, not global in nature. Second, the foci of activation identified here are consistent with those described by the PET study of Lou *et al.*, which did not find changes in global cerebral blood flow [13]. Third, while the two individuals monitored here displayed different cardiorespiratory changes during meditation, both subjects displayed similar patterns of activation.

During meditation subjects focus attention primarily on their breathing, usually on diaphragm movement or the physical sensations in the nostrils. This is a challenging task requiring constant vigilance so that the mind does not wander. Therefore we hypothesized that neural structures involved in attention would be recruited by meditation, and indeed, lateral prefrontal and parietal regions (well-established components of distributed attentional networks [22]) were strongly activated during meditation. The activation in limbic regions probably modulates autonomic output [23]. Future experiments will examine the role of these structures more directly.

Although our results are largely consistent with those of Lou *et al.* [13], there are a few discrepancies. Specifically, both studies identified regions that were absent in the other when making a meditation *vs* control contrast. These differences in results can be attributed to substantial differences in styles of meditation and experimental paradigms. For example, Lou *et al.* pooled (and separately compared) four different forms of Yoga Nidra meditation, none of which were similar to the meditation style used in the present study. Also, the control states in the two studies were not comparable; subjects in the present study were given a task that was similar to the mantra, while subjects in the Lou *et al.* study listened to a tape of verbal instructions, but performed no task.

Some structures display increasing fMRI signal throughout the meditation epochs, as evidenced by the late *vs* early statistical paradigm. In addition, more brain regions achieved statistical significance in the second scan than in the first scan with this comparison. These findings suggest that neural activity during meditation is dynamic, slowly evolving during practice. This is in agreement with the self-reports of experienced meditators, who report that subtle changes in the subjective

state continue to occur throughout the duration of meditation practice [11,12].

This study demonstrates that fMRI is useful for studying the changes in brain activity that occur during the practice of meditation. Elucidation of the biological basis of meditation will shed new light on cognitive and emotional brain processing systems elicited by the relaxation response, and hopefully lead to greater acceptance of the relaxation response as a complement to other medical treatments.

## REFERENCES

1. Linden W and Chambers L. *Ann Behav Med* **16**, 35–45 (1994).
2. Benson H, Alexander S and Feldman C. *Lancet* **2**, 380–382 (1975).
3. Caudill M, Schnable R, Zuttermeister P *et al.* *Clin J Pain* **7**, 305–310 (1991).
4. Jacobs GD, Rosenberg PA, Friedman R *et al.* *Behav Mod* **17**, 498–509 (1993).
5. Benson H, Frankel F, Apfel R *et al.* *Psychother Psychosomat* **30**, 229–242 (1978).
6. Wallace RK, Benson H and Wilson AF. *Am J Physiol* **221**, 795–799 (1971).
7. Banquet JP. *Electroencephalogr Clin Neurophysiol* **35**, 143–151 (1973).
8. Hebert R and Lehmann D. *Electroencephalogr Clin Neurophysiol* **42**, 397–405 (1977).
9. Jacobs GD, Benson H and Friedman R. *Biofeedback Self-Reg* **21**, 121–129 (1996).
10. Farrow JT and Hebert R. *Psychosom Med* **44**, 133–153 (1982).
11. Jevning R, Wilson AF and VanDerLaan EF. *Psychosom Med* **40**, 329–333 (1978).
12. Jevning R, Wallace RK and Beidbach M. *Neurosci Biobehav Rev* **16**, 415–424 (1992).
13. Lou HC, Kjaer TW, Friberg L *et al.* *Hum Brain Mapp* **7**, 98–105 (1999).
14. Herzog H, Lele VR, Kuwert T *et al.* *Neuropsychobiology* **23**, 182–187 (1990).
15. Jevning R, Anand R, Biedebach M and Fernando G. *Physiol Behav* **59**, 399–402 (1996).
16. Kwong KK, Chesler DA, Weisskoff RM *et al.* *Magn Reson Med* **34**, 878–887 (1995).
17. Bush G, Whalen PJ, Rosen BR *et al.* *Hum Brain Mapp* **6**, 270–282 (1998).
18. Gollub RL, Breiter H, Kantor H *et al.* *J Cerebr Blood Flow Metab* **18**, 724–734 (1998).
19. Talairach J and Tournoux P, *Co-planar Stereotaxic Atlas of the Human Brain. 3-D Proportional System: an Approach to Cerebral Imaging*. New York: Thieme Publishers, 1988.
20. Jiang A, Kennedy D, Baker J *et al.* *NeuroImage* **3**, S67 (1996).
21. Bush G, Jiang A, Talavage T and Kennedy D. An automated system for localization and characterization of functional MRI activations in four dimensions. In: Belliveau PFJ, Kennedy D, Rosen B and Ungerleider L, eds. *Second International Conference on Functional Mapping of the Human Brain*. Orlando, FL: Academic Press; 1996, p. S55.
22. Corbetta M. *Proc Natl Acad Sci USA* **95**, 831–838 (1998).
23. Vogt B, Finch D and Olson C. *Cerebr Cortex* **2**, 435–443 (1992).