

Detecting ‘Covert Consciousness’ in the Intensive Care Unit

- The bedside neurological examinations used to assess consciousness in patients with brain injuries are often limited by the patients’ inability to respond due to aphasia or other confounding factors.
- Researchers have reported the detection of "covert consciousness," consciousness that cannot be determined with standard bedside exams, using functional imaging techniques including fMRI and EEG.
- Studies using these functional techniques have found evidence of consciousness in up to 25% of patients in the ICU who lacked outward signs of consciousness.
- Recent work has underscored the potential of detecting clinical consciousness in hospital settings.

Clinicians have long relied on bedside behavioral examinations in assessing consciousness, but a host of confounding factors limit such examinations. Neurological deficits including aphasia, fluctuating states of consciousness and the subjectivity of clinicians’ observations can all contribute to uncertainty about the findings of the examinations.

This uncertainty can have far-reaching consequences. A series of studies conducted over the past 25 years or so points to about a 40% rate of misclassifying conscious patients as unconscious, a misjudgment that can significantly impact a patient’s prognosis and decisions about their care. In the intensive care unit (ICU), these assessments of consciousness inform decisions about withdrawal of life-sustaining therapy in traumatic brain injury (TBI) patients, decisions that are often made within three days of the patient’s hospital admission. As many as 70% of TBI deaths in the ICU result from such withdrawal.

To address these issues, researchers at Massachusetts General Hospital have been exploring the possibility of using imaging techniques such as functional magnetic resonance imaging (fMRI) and electroencephalography (EEG) to detect ‘covert consciousness’ in patients with brain injuries in the ICU. Covert consciousness is defined as consciousness that cannot be ascertained using bedside behavioral examinations, or consciousness essentially hidden from view by one or more of the confounding factors noted above. In the past several years, the Mass General team has made considerable progress in its work with covert consciousness, describing an approach to detection and reporting promising early findings.

Studies Find Evidence of Consciousness in Patients in Vegetative States, Other Disorders of Consciousness

Detection of covert consciousness was first demonstrated in a 2006 study using fMRI to image brain activity. This functional imaging technique, introduced by Mass General researchers nearly 30 years ago, can uncover such activity by noninvasively measuring cerebral blood oxygenation levels. Since the 2006 report, researchers examining covert consciousness have added the use of EEG, which can reveal changes in neural activity by recording fluctuations in the electrical currents present within the brain. Several studies have explored the potential of the techniques in examining patients in long-term care with chronic post-traumatic disorders of consciousness (e.g., coma, vegetative state or minimally conscious state). Researchers have uncovered signs of cognitive-motor dissociation in these patients by using active motor imagery tasks, such as asking patients to *imagine* moving a finger or performing some other task. If the patient responds, imaging shows activation in the associated area of the brain. The studies have also demonstrated measurement of higher-order cortex responses to passive language and music stimuli. Researchers believe that language and music stimuli can help shed light on function in the left and right sides of the brain, respectively.

In the years following publication of the initial findings, researchers made important strides in understanding covert consciousness in patients in long-term care. Open questions remained, however, about the detection of covert consciousness in the ICU, where early identification can play a critical role in clinical decision-making. To address these questions, Mass General researchers performed imaging studies on 16 patients admitted to the ICU for acute severe traumatic brain injury. The results, reported in 2017 in the journal *Brain*, underscored the importance of the ability to detect covert consciousness in the ICU. Using fMRI and EEG, the researchers found evidence of such consciousness in four patients, including three whose bedside neurological examinations suggested a vegetative state. In two other patients who showed no outward signs of language function, imaging with language and music stimuli revealed higher-order cortex responses to the stimuli.

One of the cases illustrates the potential impact of detecting covert consciousness in the ICU. The first patient enrolled in the study had been struck by a car and brought to the Mass General Neurosciences ICU. Unresponsive to voices, bright lights or normal touch, he was determined to be minimally conscious, a classification one step above a vegetative state. The doctors in the ICU feared he might never fully regain consciousness. When the doctors put him in a scanner and played him various recordings, however, the language area of his brain activated in response to speech and the auditory area activated in response to music. The results of the scan suggested at least a possibility of recovery. A couple of days later, the patient began to wake up.

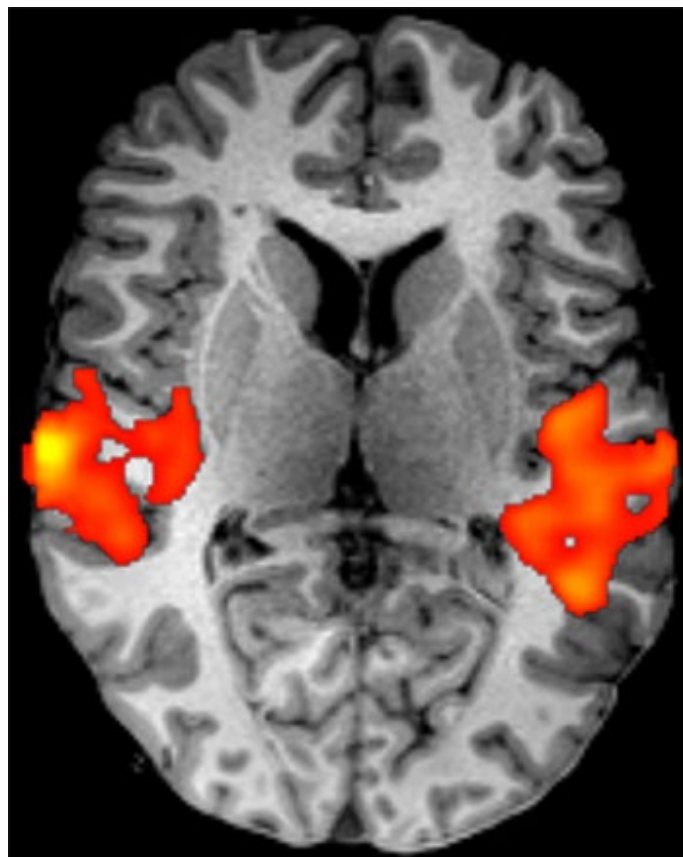


Figure 1. This functional MRI scan was acquired from a patient in the ICU who had been struck by a car. Though he was determined to be minimally conscious, the scans showed that language-associated areas of his brain activated (orange in the scan) when speech was played to him through headphones. He eventually fully regained consciousness.

Recent Research Highlights the Potential of Detecting Covert Consciousness for Clinical Application

In a paper published last year in the *New England Journal of Medicine*, a team of researchers at Columbia University and New York University reported a study in which they performed task-based EEG on 104 patients in the ICU with acute brain injuries. The group was the largest cohort of such patients in a study of covert consciousness. The researchers found evidence of covert consciousness in 16 of the total patients (15%). For the first time, the findings also showed covert consciousness detected by EEG was associated with better functional outcomes one year after injury.

The study underscored the potential of detecting covert consciousness in patients with acute brain injuries in the ICU. At the same time, the correlation between early detection and favorable long-term outcomes and the fact that the study used only EEG recommend the approach for use in clinical practice. Since EEG is inexpensive and portable, especially compared to fMRI, and can be performed safely at the bedside, it could be widely deployed for detection of covert consciousness in ICUs and other settings around the world.

Further Information

For more information about detection of covert consciousness in the ICU, please contact [Brian Edlow, MD](#), Director of the Laboratory for NeuroImaging of Coma and Consciousness (NICC), Massachusetts General Hospital. We would like to thank Dr. Edlow for his advice and assistance in preparing this article.

References

Claassen J, Doyle K, Matory A, et al. Detection of Brain Activation in Unresponsive Patients with Acute Brain Injury. *N Engl J Med*. 2019;380(26):2497–2505.

Edlow BL, Chatelle C, Spencer CA, et al. Early detection of consciousness in patients with acute severe traumatic brain injury. *Brain*. 2017;140(9):2399–2414.

Edlow BL, Fins JJ. Assessment of Covert Consciousness in the Intensive Care Unit: Clinical and Ethical Considerations. *J Head Trauma Rehabil*. 2018;33(6):424–434.

Giacino JT, Edlow BL. Covert Consciousness in the Intensive Care Unit. *Trends Neurosci*. 2019;42(12):844–847.

Owen AM, Coleman MR, Boly M, Davis MH, Laureys S, Pickard JD. Detecting awareness in the vegetative state. *Science*. 2006;313(5792):1402.

©2020 MGH Department of Radiology

Gary Boas, Author
Raul N. Uppot, M.D., Editor

