

# Functional Stealing : Reorganization of the Retinotopic Map After Occipital Lobe Infarction

Lucia M. Vaina, M.D., Ph.D.<sup>1,2,3</sup>, Sergei Soloviev, M.S.<sup>3</sup>, Ferdinando Buonanno, M.D.,<sup>1,2</sup>

<sup>1</sup> Massachusetts General Hospital, Department of Neurology, Boston, MA, USA, 02214

<sup>2</sup> Harvard Medical School, Department of Neurology, Boston, MA, USA, 02215

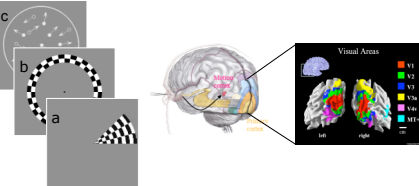
<sup>3</sup> Boston University, Departments of Biomedical Engineering and Neuroscience, Boston, MA, USA, 02215  
lvaina@partners.org, serges@bu.edu, fbuonanno@partners.org

## Background

While neuroplasticity after stroke has been amply demonstrated using functional magnetic resonance imaging (fMRI) in the motor (1-4) and language (5) systems, there is a dearth of human studies examining neuroplasticity in the cortical visual system. This is in stark contrast with the extensive knowledge of visual mechanisms and their neural substrate in non-human primates and humans.

## Aims

We used repeated fMRI to quantify functional reorganization after stroke affecting the visual system, and correlate such reorganization with training-related changes in performance on behavioral visual motion tasks. The known detailed organization of the visual areas in the human occipital lobe allowed us to conduct a quantitative study.



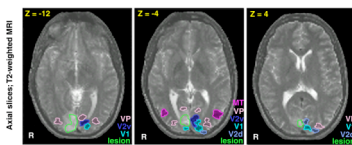
## Methods

The stimuli used in the fMRI studies were rotating wedges (a) expanding rings (b) consisting of flickering checkerboard patterns (2Hz rate), a full field flickering checkerboard stimulus (not shown), and "motion coherence" which was a random dot kinematogram display (c) where a proportion of the dots moved radially in expanding or contracting motion while the remainder dots provided masking motion noise. These first three stimuli allowed us to map the retinotopic visual areas and the Motion Coherence task localized the MT+ cortical region, an area known to be especially involved in processing visual motion (6,7,8). All tasks were performed with central fixation and in both, observers fixated the center of the screen. For the retinotopic mapping subjects were asked to perform a fixation discrimination task (press a key on a magnet compatible keypad every time the fixation changed luminance). In the Motion Coherence task subjects discriminated direction in the radial pattern motion stimulus.

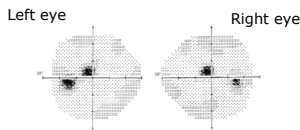
## Subjects

Patient referred to as JS is 25 a year old right handed man who suffered an infarct in the right occipital lobe involving the lingual gyrus and cuneus (BA17,18). For eight months, the patient underwent weekly psychophysical testing and retraining of visual motion deficits.

He also underwent three fMRI studies: 3, 8, and 11 months after the stroke.



Retinotopic mapping in the first fMRI obtained 3 months after JS's infarct showed that the retinotopic areas V1, V2v, VP and slightly V2d were involved in the cortical aspect of his lesion. Consistent with the predominant ventral location of the lesion, neuro-ophthalmological examination revealed a homonymous left upper quadrant scotoma (~2° off midline just above the horizontal).



Three age and sex matched normal controls were used for comparison in the fMRI studies and 5 in the psychophysical studies.

Informed Consent according to the Massachusetts General Hospital, Martino's Center for Biomedical Imaging and Boston University IRB committees was obtained from all subjects.

## Behavioral tasks and fMRI

JS underwent several months of training with a variety of psychophysical visual motion tasks. Here we illustrate changes in his performance in the Motion Coherence task.

The stimulus consists of a random dot kinematogram presented in a circular aperture 10 deg in diameter. A variable proportion of the dots (signal dots) moved on a radial trajectory (expansion or contraction) while the remainder dots provided masking motion noise. The subjects are asked to discriminate the net direction of the stimulus motion (expansion or contraction). The difficulty of the stimuli is titrated by an adaptive staircase procedure (9) that changed in the function of the proportion coherence needed by subjects to give a reliable response (79% correct). The figure shows thresholds from 5 matched normal control subjects and from JS. JS data is shown over 22 sessions, spaced over 8 months. The control subjects required less than 10% coherence to accurately perform the task for stimuli presented in the upper right or left quadrant or for fixation in the center. Initially JS's performance was quite impaired and in the Upper left quadrant (corresponding to his right occipital lobe lesion) he could not do the task at all. Data shows that his performance in both visual fields improved. At the time of the first fMRI (3month-after lesion), his threshold was less than 30% coherence in either quadrant, and 20% with central fixation. His performance continued to improve, at the second fMRI scan obtained at 8 months after the lesion, threshold on central fixation was 10%. And finally, at 11 months his performance was better than that of the control subjects, 5% coherence.

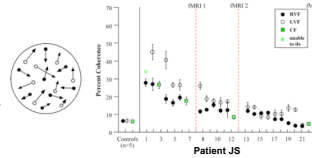
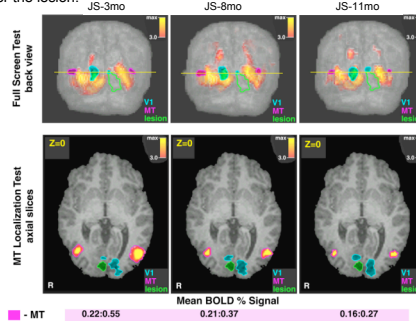


Figure below shows activations in JS for the full screen checkerboard (top) and activation from the Motion Coherence task at 3,8,11 months after the lesion.

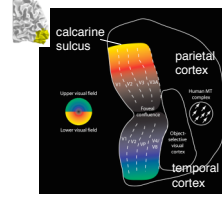


The fMRI BOLD signal change shows a pattern similar to that seen in the normal subjects with perceptual learning tasks. With performance improvement the MT+ activation in JS becomes smaller. The area MT+ was not involved in JS's lesion, yet initially, his performance was impaired due perhaps too poor input from the area V1 and V2, both projecting to MT (10).

## Longitudinal changes in the retinotopic areas

Retinotopic areas are organized topographically, as shown. The topography respects the projection from the upper (in green/blue) and lower (in red/yellow) visual fields.

This organization is respected in JS retinotopic maps of the left and right occipital lobes. However, the areas (shown in mm sq in the table) change dramatically over time.



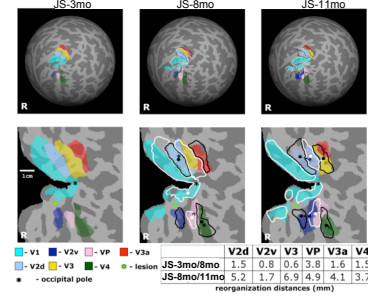
LEFT HEMISPHERE - PATIENT JS AND Controls (C1,C2,C3)	
	JS-3mo JS-8mo JS-11mo C1 C2 C3
V1	2074 2956 1205 4379 4061 8791
V2d	251 210 109 454 454 454
VP	654 432 224 595 579 582
V3	435 314 144 361 359 371
V3a	452 388 433 440 431 381
V4	316 156 189 229 223 274
V4a	353 166 197 229 223 274
V5	338 274 254 214 224 254
MT+	253 104 203

RIGHT HEMISPHERE	
	JS-3mo JS-8mo JS-11mo C4 C5 C6 C7 C8 C9 C10
V1	78 84 244 478 481 482 491 309 438
V2d	43 14 16 23 23 23 23 23 23
VP	69 172 212 394 374 348 322 215
V3	42 16 16 23 23 23 23 23 23
V3a	268 195 172 212 192 223 215 119 213
V4	24 25 156 213 203 278 261 300 291
V4a	48 24 156 213 203 278 261 300 291

## Shifts over time of the retinotopic areas in the damaged hemisphere

The preserved topography but the significant changes in magnitude of the retinotopic areas raised the question of how these areas relate to each other over time. To answer this question we re-represented the retinotopic maps in spherical coordinates and measured the shift over time (between scan 1-2; between scan 2-3). The contours on the flattened map representation illustrate the shifts in the center of mass of the retinotopic areas in JS- Right hemisphere, and the table quantifies the amount of shift.



The lesion in the right hemisphere involved the retinotopic areas V2d, V2v, VP and V1. The figure shows that the most dramatic shift occur between 8 months-11 months, in areas V2d-V3-V3a. Only V2d was involved in the lesion: gaining functional area over time (more than 50% ) appeared to cause loss of functional area in the adjacent intact areas, V3 and V3a. Shifts in V2v-VP-V4 , the ventral stream, had a lesser shift, in part perhaps because both adjacent areas V2v and VP were lesioned. But since V4 was intact, VP could extend into V4 (4.9 mm shift) while gaining functional space (90% between 3 months and 8months after the lesion; and additional 23% between 8 and 11 months).

The table below shows that significant shifts of these early visual areas are particular to the cortical dynamics of lesioned hemisphere, and they are not noted in the normal hemisphere or control subjects.

JS Left Hemisphere	V2d	V2v	V3	VP	V3a	V4
3mo/8mo	0.8	1.5	0.4	1.5	1.1	1.9
8mo/11mo	0.8	1.5	0.0	1.2	1.5	1.2
Control (5)	0.0	0.0	0.2	0.4	0.2	0.5
Right Hemisphere	0.0	0.0	0.0	0.0	0.0	0.0
Left Hemisphere	0.5	0.2	0.0	0.5	0.2	0.2

Orderly map in the lesioned right hemisphere with retinotopic topography preserved but shifted—key to functional recovery?

## Conclusions

Extent of shift and change in areas' surface demonstrate lesion-dependent large-scale reorganization in circumlesional retinotopic maps. Topography was maintained, but there was a dramatic functional stealing from nearby intact areas by the areas involved in the lesion and recruited during the patient's retraining with various visual motion tasks.

## References

- Dobkin B. "Neurology of Rehabilitation" Ann. N.Y. Acad. Sci. 1038:148-170
- Ward N. et al. "neural correlates of motor recovery after stroke: a longitudinal fMRI study", Brain, 126 (11) 2476-2496
- Thulborn, K et al. "Plasticity of Language-Related Brain Function During Recovery From Stroke" Stroke, 1999; 30:749-754
- Yue Cao et al. "Cortical Language Activation in Stroke Patients Recovering From Aphasia With Functional MRI", Stroke, (1999) 30: 2331-2340
- Cornelissen et al Adult brain plasticity elicited by anomia treatment, J. Cogn. Neurosci., 15 (2003) (3), pp. 444-461
- Movshon, JA and Newsome, WT (1992). Neural foundations of visual motion perception. Current Directions in Psychological Science. 1:35-39.
- Vaina LM. (1998). "Complex motion perception and its deficits." Curr Opin Neurobiol., 8(4): 494-502.
- Vaina LM, Cowey A, Eskew RT Jr, LeMay M, Kemper T. (2001). "Regional cerebral correlates of global motion perception: evidence from unilateral cerebral brain damage." Brain, 124(Pt 2): 310-321.
- Vaina LM, Gryzwacz NM, Salviroonp P, LeMay M, Bienfang DC, Cowey A. (2003). "Can spatio-temporal motion integration overcome deficits in local motion mechanisms?" Neuropsychologia, 41: 1817-1836
- Movshon, JA and Newsome, WT (1996). Visual response properties of striate cortical neurons projecting to area MT in macaque monkeys. J. Neurosci. 16(23): 7733-7741