

Modified En Bloc Spondylectomy for Tumors of the Thoracic and Lumbar Spine

Surgical Technique and Outcomes

Akash A. Shah, BS, Nuno R. Paulino Pereira, MD, Frank X. Pedlow, MD, John C. Wain, MD, Sam S. Yoon, MD, Francis J. Hornicek, MD, PhD*, and Joseph H. Schwab, MD, MS*

Investigation performed at Massachusetts General Hospital, Boston, Massachusetts

Background: Total en bloc spondylectomy (TES) for the treatment of spinal tumors decreases local recurrence and improves survival compared with intralesional resection. TES approaches vary in both the number of stages to complete the procedure and instruments with which osteotomies are performed.

Methods: We describe a 2-stage technique that employs the use of threadwire saws. We performed a retrospective review of cases of primary tumors and solitary metastases involving the thoracic or lumbar spine treated with use of our modified technique at our institution between 2010 and 2016, identifying eligible patients by searching for specific phrases in operative reports found in our oncologic database. Clinical notes, operative notes, imaging reports, and pathology reports were reviewed for all patients.

Results: Thirty-three patients underwent our modified technique, in which we pass a threadwire saw between the vertebral body and the thecal sac. The most common tumor type was chordoma (64%), and tumors were most commonly located in the lumbar spine (61%). There were no intraoperative injuries to the spinal cord or great vessels. One patient experienced a dural tear secondary to the passage of a saw. Seventeen (52%) of the patients had perioperative complications, with 1 death. Seven (22%) of the patients had complications occurring within 90 days after discharge, and 8 (25%) had complications occurring >90 days after discharge. Instrumentation failure was observed in 8 cases (25%). Negative margins were obtained in 94% of the cases. Local recurrence was observed in 2 cases (6%). The majority of patients had normal motor function at the time of the most recent follow-up.

Conclusions: Our modified en bloc spondylectomy represents an effective technique for the resection of spinal tumors in selected patients, allowing for visualization of vessels anterior to the spine and the avoidance of spinal cord injury.

Level of Evidence: Therapeutic Level IV. See Instructions for Authors for a complete description of levels of evidence.

Achieving negative tumor margins has long been a challenge in the surgical management of spinal tumors, as the proximity of the vertebral column to major neurovascular structures makes achieving negative margins difficult¹⁻³. In the past, surgery was largely limited to curettage and intralesional resection, which were associated with high local recurrence rates^{4,5}. There has been a progression toward the use of total en bloc spondylectomy (TES), which involves removing the entire vertebral body and posterior elements fully encased within a layer of healthy tissue, similar to the management of bone tumors of the extremities⁵⁻¹⁰. TES has been shown to improve survival and local control

compared with piecemeal resection for primary spinal tumors¹¹⁻¹⁸.

Multiple TES approaches have been described: single-stage posterior^{1,7,8,19-21}, single-stage combined anterior-posterior²²⁻²⁴, and 2-stage approaches^{5,25-28}. Furthermore, there is variability in the instruments with which osteotomies in these procedures are performed (e.g., Gigli saws, osteotomes, high-speed burrs, and threadwire saws)^{1,7,25,28-31}. Damage to vessels anterior to the vertebral column is a common cause of morbidity associated with all TES procedures, particularly single-stage posterior approaches, due to a lack of visualization of anterior structures^{32,33}.

*Francis J. Hornicek, MD, PhD, and Joseph H. Schwab, MD, MS, contributed equally to the writing of this article.

Disclosure: No external funding was received for this study. The **Disclosure of Potential Conflicts of Interest** forms are provided with the online version of the article (<http://links.lww.com/JBJS/E288>).

TABLE 1 Major and Minor Complications Defined*

Type of Complication	Major	Minor
Pulmonary	Pneumonia, respiratory failure requiring intubation	Transient hypoxia
Operative wound	Infection requiring operative debridement	Necrosis at the edge of wound
Hematologic	Deep-vein thrombosis	Multiple postop. transfusions
Operative	Injury to great vessel	Dural tear
Neurologic	New plegia, stroke, seizure	Transient dysesthesias, transient confusion
Renal	Acute kidney injury requiring hemodialysis	Acute kidney injury not requiring hemodialysis
Cardiac	Cardiac arrest, catheterization, congestive heart failure	Atrial fibrillation responding to medication

*Reproduced, with modification, from: McDonnell MF, Glassman SD, Dimar JR 2nd, Puno RM, Johnson JR. Perioperative complications of anterior procedures on the spine. *J Bone Joint Surg Am.* 1996 Jun;78(6):839-47.

We use a modified approach that may reduce the risk of damage to critical neurovascular structures. Our primary study aim was to describe this technique in detail. Secondarily, we describe intraoperative, perioperative, and long-term complications as well as oncologic outcomes among 33 patients who underwent this procedure at our institution.

Materials and Methods

Study Design and Subjects

Our institutional review board approved this retrospective study. We included all patients >18 years of age who underwent a 2-stage TES performed with use of threadwire saws for the treatment of a spinal tumor, between 2010 and 2016, at 1 tertiary care center. We excluded patients in whom a single-stage posterior approach was used.

We identified our cohort from an oncologic database containing 59,039 unique patients who visited our clinic between 1979 and 2015. A computer search in which we queried the patients' operative notes for "threadwire saw" and its synonyms yielded 43 potentially eligible patients. We consulted our surgery schedule to identify 12 additional patients after 2015. After screening these 55 patients, 33 were found to have undergone the 2-stage procedure and were included in this study. The other 22 patients had undergone a single-stage procedure and were excluded.

Outcome and Other Variables

Data regarding patient age, sex, tumor histology, and neoadjuvant therapy were obtained from a review of clinical notes. Tumors were staged according to the system described in the recently published eighth edition of the *AJCC* (American Joint Committee on Cancer) *Cancer Staging Manual*³⁴. Motor

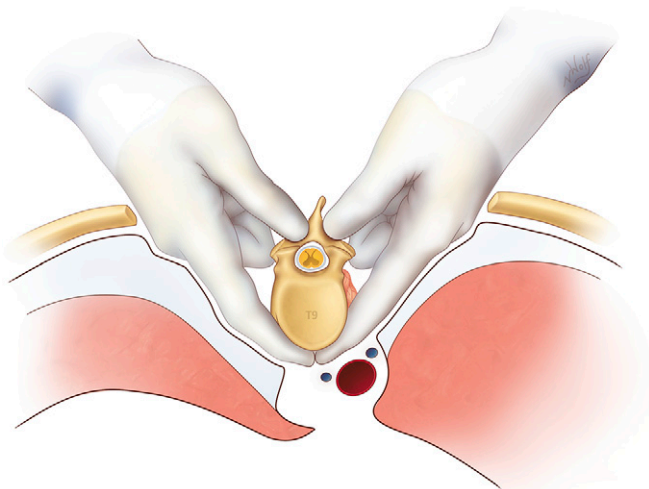


Fig. 1

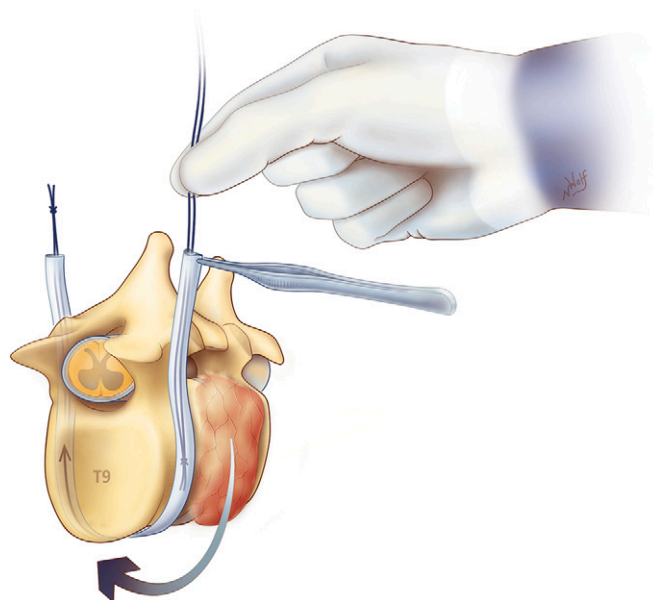


Fig. 2

Fig. 1 Blunt dissection is performed to develop a plane between the vertebral body and the great vessels. (Illustration by Nicole Wolf, MS, ©2016. Printed with permission.) **Fig. 2** Following dissection, a Penrose drain is passed anterior to the vertebral body but posterior to the great vessels. Then, threadwire saws are passed into the sheath and tied together. This is performed both cephalad and caudad to the tumor. (Illustration by Nicole Wolf, MS, ©2016. Printed with permission.)

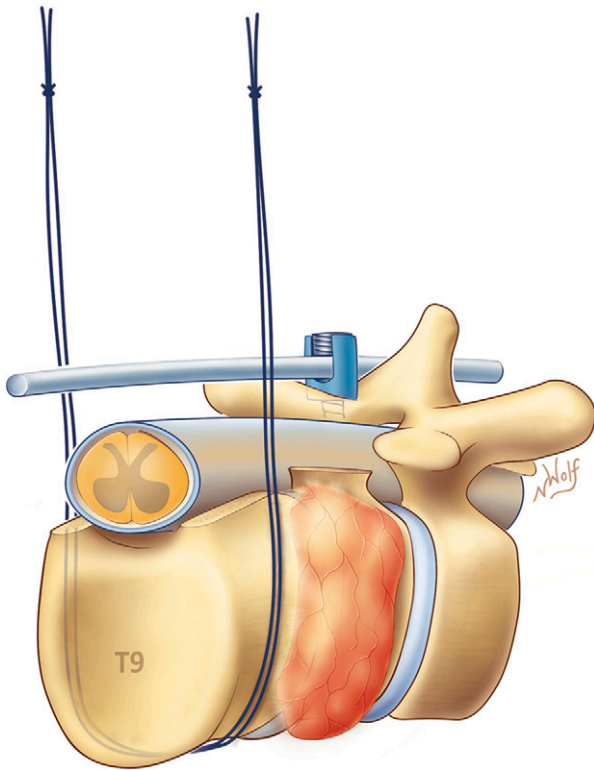


Fig. 3

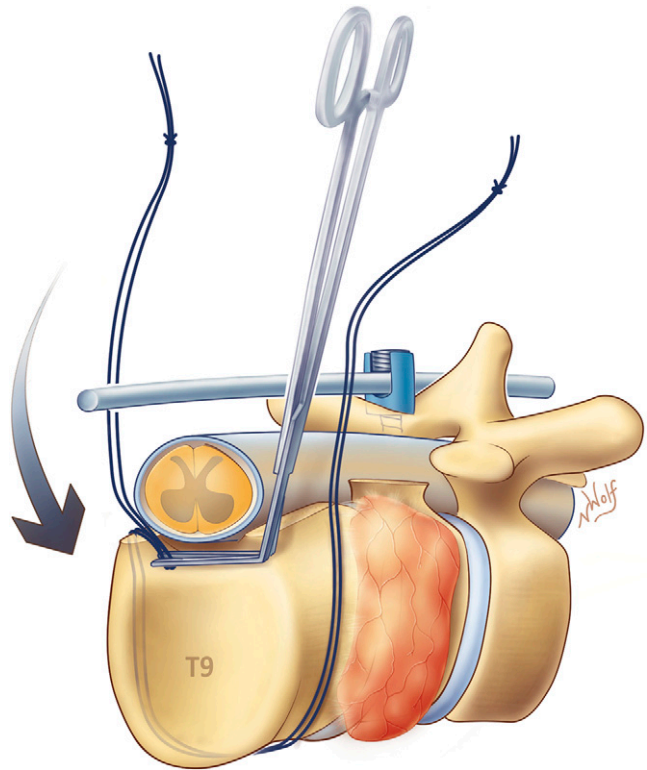


Fig. 4

Fig. 3 Decompressive laminectomies and the removal of posterior elements are performed using either threadwire saws or a high-speed burr and Kerrison rongeurs. (Illustration by Nicole Wolf, MS, ©2016. Printed with permission.) **Fig. 4** A plane is developed anterior to the thecal sac and posterior to the vertebral body. One end of each threadwire saw is passed through this plane, and the saws are lassoed around the vertebral body. (Illustration by Nicole Wolf, MS, ©2016. Printed with permission.)

function was evaluated according to the American Spinal Injury Association Impairment Scale³⁵. Performance status was scored according to the Eastern Cooperative Oncology Group system³⁶.

Estimated blood loss, intraoperative complications, and total operative time were obtained from operative notes. We identified injury to the spinal cord, vessels, and dura as potential complications that could plausibly be due to

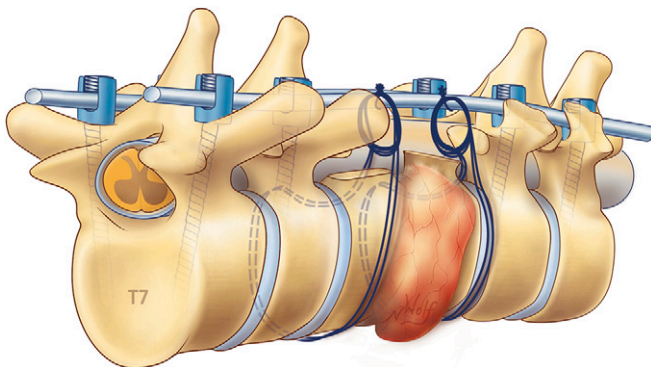


Fig. 5

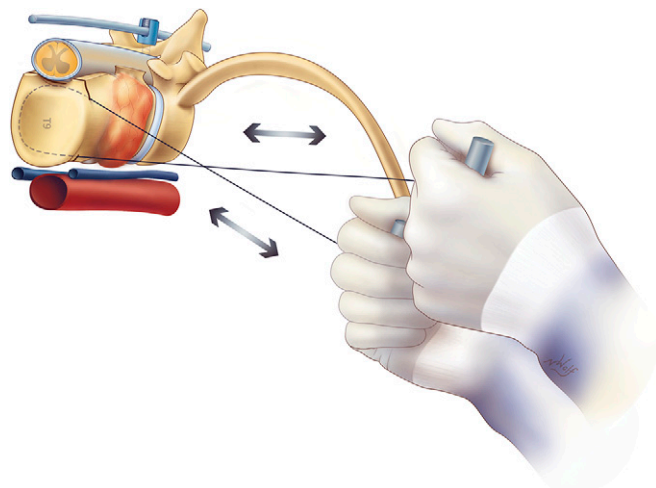


Fig. 6

Fig. 5 The ends of the threadwire saws are sutured in a loop and secured to the posterior hardware. (Illustration by Nicole Wolf, MS, ©2016. Printed with permission.) **Fig. 6** We resect the tumor in the second, anterior stage by crossing the hands to aid with the ergonomics of sawing, with subsequent sawing in an anterolateral direction (i.e., away from the spinal cord). This is done for the cephalad and caudal osteotomies. (Illustration by Nicole Wolf, MS, ©2016. Printed with permission.)

TABLE II Baseline Characteristics (N = 33)

Age* (yr)	58 (44-64)
Male sex (no. [%])	20 (61)
Tumor histology (no. [%])	
Chordoma	21 (64)
Chondrosarcoma	9 (27)
Other†	3 (9.1)
Recurrent tumor (no. [%])	7 (21)
Location of tumor (no. [%])	
Lumbar spine (L1-L5)	20 (61)
Thoracic spine (T1-T12)	12 (36)
Thoracolumbar spine (T1-L5)	1 (3.0)
No. of involved vertebral levels (no. [%])	
1	16 (48)
2	7 (21)
3	9 (27)
4	0 (0)
5	0 (0)
6	1 (3.0)
Tumor stage‡ (no. [%])	
T1NOMO	7 (23)
T2NOMO	4 (13)
T3NOMO	1 (3.3)
T4aNOMO	16 (53)
T4aNOM1a	1 (3.3)
T4aNOM1b	1 (3.3)
Extrasosseous extension (no. [%])	
Epidural space	18 (55)
Paraspinal muscles	5 (15)
Paravertebral soft tissue	5 (15)
Chest wall	2 (6.1)
Preop. radiation therapy (no. [%])	29 (88)
Chordoma§	21 (72)
Chondrosarcoma§	7 (24)
Malignant solitary fibrous tumor§	1 (3.4)
Preop. radiation dose* (Gy)	50.4 (50.4-50.4)
Preop. chemotherapy (no. [%])	4 (12)
Preop. motor function (no. [%])	
Normal	29 (88)
Preserved, muscle grade ≥3 below tumor level	4 (12)
Preserved, muscle grade <3 below tumor level	0 (0)
Preop. performance status (no. [%])	
Fully active at predisease performance level	15 (45)
Active but restricted in strenuous activity	17 (52)
Ambulatory, unable to carry out work activities	0 (0)
Capable of only limited self-care	1 (3.0)
Completely disabled	0 (0)

*The values are given as the median, with the interquartile range in parentheses. †Other tumors included metastatic leiomyosarcoma (n = 1), metastatic mixed germ cell tumor (n = 1), and solitary fibrous tumor (n = 1). ‡Stage provided for the 30 tumors with chordoma or chondrosarcoma histology. §The percentage shown is of the number of patients (n = 29) who had preoperative radiation therapy.

the passage of saws. Long-term complications and oncologic outcomes were assessed through follow-up clinical notes. Surgical margins were assessed through pathology reports. Perioperative complications were categorized according to the classification of perioperative complications of anterior spinal procedures as described by McDonnell et al.³⁷ (Table I). We evaluated patients for recurrent disease through magnetic resonance imaging (MRI), which was obtained every 3 months for the first 2 years post-discharge, followed by every 6 months. All patients had at least 6 months of follow-up.

Thirty patients had complete data regarding the variables recorded. There were 2 patients for whom the total operative time was unavailable and 1 patient for whom surgical margins could not be obtained due to an aborted tumor resection.

Treatment

There are important anatomical considerations based on tumor location. In the upper thoracic spine, attention should be directed to venous structures (i.e., the azygos and hemiazygos system), as arterial inflow is above the level of the aortic arch. Care must be taken to identify radiculomedullary arteries that supply the anterior spinal artery. There are fewer radiculomedullary arteries in the thoracic spine and they are more spread out than in other spinal regions, contributing to poor collateral circulation potential³⁸.

Similarly, the unique anatomy of the lumbar spine must be considered. The proximity of the vertebrae to the aorta, the inferior vena cava, and the iliac veins poses a challenge for TES in this region. The large origin of the iliopsoas muscles on the lumbar spine requires a trans-psoas approach for adequate exposure of the spine. Furthermore, while lumbar nerve roots may be intentionally sacrificed to ensure adequate margins, care must be taken to avoid unintended injury when possible, given the importance of the lumbar plexus for lower-extremity function. What follows is a generalized technique, but it is crucial that the relevant local anatomy be considered in the approach to each specific case.

Our technique consists of 2 stages. For the first stage, in which a posterior approach is used, the patient is placed in a prone position. The surgeon makes a midline posterior incision over the affected levels, and the paraspinous

TABLE III Hospital Course (N = 33)

Intraop. complications (no. [%])	9 (27)
Dural tear*	9 (100)
Dural tear due to passage of saw*	1 (11)
Vessel injury*	0 (0)
Spinal cord injury*	0 (0)
Intraop. dural plaque placement (no. [%])	16 (48)
Periop. complications† (no. [%])	17 (52)
Major‡	11 (65)
Minor‡	6 (35)
Total operative time§ (hr)	14.2 (12.2-17.6)
Estimated blood loss§ (L)	6.0 (4.2-7.5)
Intraop. radiation dose§ (Gy)	10 (10-10)
Hospitalization duration§ (days)	17 (13-26)

*The percentage shown is of the number of patients (n = 9) who had intraoperative complications. †McDonnell classification as described in Table I. ‡The percentage shown is of the number of patients (n = 17) who had perioperative complications. §The values are given as the median, with the interquartile range in parentheses.

TABLE IV Perioperative Complications

Complication	Major, N = 11	No.	Minor, N = 6	No.
Pulmonary	Pneumonia	2	Pleural effusion requiring diuretic	1
	Respiratory distress requiring intubation	2		
	Pneumothorax with chest tube placement	1		
	Pleural effusion with chest tube placement	1		
Operative wound	Infection requiring debridement	1	Infection treated with antibiotics	1
Neurologic	Seizure requiring anticonvulsant	1	Cerebrospinal fluid leak	2
Renal	Acute kidney injury requiring hemodialysis	1		
Cardiac	Myocardial infarction	1	Atrial fibrillation responding to rate control	1
			Tachycardia responding to rate control	1
	Death	1		

muscles are dissected to expose the posterior osseous elements of the spine. Blunt dissection is performed to develop a plane between the vertebral body and the great vessels (Fig. 1). The aorta and its branches are relatively resistant to tearing. In the lumbar spine, care must be taken to avoid tearing the inferior vena cava or lumbar veins, given that the dissection around the lateral and anterior aspects of the vertebral body is done blindly. Initial dissection can be performed with a fine Adson clamp or right-angle clamp, and the tunnel can be progressively enlarged with a blunter clamp. The dissection should stay to the right of the vertebral body and the anterior longitudinal ligament and approach the anterior aspect of the vertebral body from both the right and left sides. Slowly, the tunnel is completed circumferentially and enlarged enough to accommodate a large vascular clamp with a half-circle clamp configuration (e.g., DeBakey Aorta Clamp, item AL2125.1; Wexler Surgical). A quarter-inch (0.64-cm) Penrose drain is then passed with a vascular clamp through this plane anterior to the vertebral body but posterior to the great vessels; threadwire saws (Mani Diamond Tomita-Saw, item 0106132; Mani) are then passed into the sheath and tied together (Fig. 2). This is done at 2 levels: cephalad and caudad to the tumor. After confirming on an intraoperative radiograph or computed tomography (CT) image that the saws are in the appropriate position, decompressive laminectomies and removal of the posterior elements are performed using either threadwire saws or a high-speed burr and Kerrison rongeurs (Fig. 3).

For cases involving the thoracic spine, the ribs are cut to access the thoracic cavity, where segmental nerve roots are identified and ligated. For lumbar cases, we develop a plane lateral to the vertebral body and medial to the psoas muscle, identifying and protecting traversing nerve roots. At this point for lumbar or thoracic cases, we develop a plane anterior to the thecal sac and posterior to the vertebral body. The Penrose drain is removed, and 1 end of each saw is passed through this plane between the thecal sac and the posterior longitudinal ligament. The saws are lassoed around the vertebral body (Fig. 4). Posterior instrumentation is subsequently performed at least 2 levels cephalad and caudad to the tumor. The ends of the threadwire saws are coiled and sutured in a loop, and secured to the posterior instrumentation in preparation for the second stage (Fig. 5). Closure is then performed. We obtain a CT image between stages to document the location of the saws relative to major vessels.

One to 7 days after the first stage, the second stage, involving an anterior approach, is performed. The patient is placed in a lateral position and a thoracotomy (thoracic tumors) or flank incision (lumbar tumors) is performed. We identify the saws anchored to the instrumentation and release them by cutting the suture. We begin with the caudal or cephalad osteotomy by crossing the hands to aid with the ergonomics of sawing, and saw in an anterolateral direction, away from the spinal cord (Fig. 6). The hand pulling the saw between the thecal sac and the intervertebral disc or vertebral body is directed into the disc in order to prevent injuring the dura. This is repeated for the remaining cephalad or caudal osteotomy. As the tumor is gently

mobilized, we dissect the thecal sac away from the vertebral body and tumor. The specimen is removed en bloc and sent for pathologic analysis. For patients with dural disease, intraoperative irradiation is then performed via dural plaque application. Finally, anterior spinal fusion with instrumentation is performed, most commonly using a vascularized fibular autograft. The vascularized fibula is removed and flushed copiously with heparinized saline solution through the arterial inflow. The graft is sized to fit the spinal defect and compressed between the end plates. Microvascular re-anastomosis is performed, with subsequent closure. In certain cases, interbody cages or allografts are used for anterior fusion.

TABLE V Long-Term Complications (N = 32) *

Complications within 90 days after discharge (no. [%])	7 (22)
Infection†	2 (29)
Deep-vein thrombosis†	2 (29)
Instrumentation failure†	1 (14)
Cerebrospinal fluid leak†	1 (14)
Fever of unknown origin†	1 (14)
Complications >90 days after discharge (no. [%])	8 (25)
Instrumentation failure‡	7 (88)
Cerebrospinal fluid leak‡	1 (13)
Reoperation required§ (no. [%])	14 (44)
Indication for reoperation§ (no. [%])	
Failure of instrumentation	8 (25)
Wound infection	6 (19)
Local recurrence	2 (6.3)
Time to instrumentation failure# (wk)	39 (23-42)

*One patient died perioperatively and thus had <6 months of follow-up; the patient was excluded from this analysis. †The percentage shown is of the number of patients (n = 7) with complications within 90 days after discharge. ‡The percentage shown is of the number of patients (n = 8) with complications >90 days after discharge. §One patient required reoperation for instrumentation failure and a recurrent tumor, and 1 patient required reoperation for instrumentation failure and a wound infection. #The values are given as the median, with the interquartile range in parentheses.

TABLE VI Oncologic and Long-Term Outcomes (N = 32)*

Negative margins (no. [%])	30 (94)
Tumor recurrence (no. [%])	2 (6.3)
New metastasis (no. [%])	2 (6.3)
Motor function at last follow-up (no. [%])	
Normal	25 (78)
Preserved, muscle grade ≥ 3 below tumor level	7 (22)
Preserved, muscle grade < 3 below tumor level	0 (0)
Performance status at last follow-up (no. [%])	
Fully active at predisease performance level	8 (25)
Active but restricted in strenuous activity	14 (44)
Ambulatory, unable to carry out work activities	8 (25)
Capable of only limited self-care	1 (3.1)
Completely disabled	1 (3.1)
Direct clinical follow-up† (wk)	72 (33-104)

*One patient died perioperatively, and was thus excluded from this analysis. †The values are given as the median, with the interquartile range in parentheses.

In thoracic cases, we generally separate the parietal pleura from the vertebral body in order to pass the saws between the thecal sac and the vertebral body. In this scenario, the pleura is not used as an oncologic margin. In cases in which the lung is involved, however, the pleura is left on the tumor and is resected with the tumor in a single en bloc specimen.

For tumors that extend into the epidural space, careful dissection must be performed before placing the saws between the thecal sac and the vertebral body. In cases in which the dura can be easily elevated, blunt dissection is performed using a Penfield number-4 dissector. If the tumor is adherent to the dura, sharp dissection with Stevens tenotomy scissors is performed. In both cases, intraoperative radiation is indicated.

Ideal candidates for this procedure are patients with nonmetastatic primary spinal tumors for whom there are no effective adjuvants and who are medically well enough to undergo the surgery and be rendered disease-free from it. Rarely, we operate on patients with solitary metastasis to the spine who are well enough to undergo the procedure. Any patient with multi-organ metastasis from a primary spinal tumor is not a candidate.

Statistical Analysis

We present categorical variables as the number and frequency, and continuous variables as the median and interquartile range (IQR). We used Stata/SE software (version 12; StataCorp) for statistical analyses.

Results

Baseline Characteristics

We included 33 patients with a median age of 58 years (IQR, 44 to 64 years). Twenty (61%) of the patients were male. The tumor histology was as follows: chordoma (n = 21), chondrosarcoma (n = 9), metastatic leiomyosarcoma (n = 1), metastatic mixed germ cell tumor (n = 1), and solitary fibrous tumor (n = 1). The primary site of the leiomyosarcoma was the

tibia, and the primary site of the mixed germ cell tumor was the anterior mediastinum. There were 20 lumbar tumors (61% of the patients), 12 thoracic tumors (36%), and 1 spanning the thoracolumbar junction (3%). Tumors most commonly involved 1 vertebral level (48%). The most common primary spinal tumor stage based on the AJCC system was T4aN0M0, indicating extension into the epidural space. Eighteen (55%) of the patients in total had epidural extension. Five patients had extraosseous extension into the paraspinous muscles, 5 had extension into the paravertebral soft tissue, and 2 had chest-wall involvement (Table II).

Preoperative Characteristics

Twenty-nine (88%) of the patients received preoperative radiation therapy. The typical dose was 50.4 Gy, as established in a previous study by our treatment team³⁹. All 21 cases of chordoma as well as 7 of the chondrosarcoma cases received preoperative radiation. Twenty-nine (88%) of the patients had normal motor function at the time of surgery. Patients had high activity status preoperatively, with 32 (97%) either fully active at the predisease performance level or restricted only in physically strenuous activity (Table II).

Hospital Course

Nine (27%) of the patients experienced an intraoperative dural tear. No patient had injury to the spinal cord or great vessels. One tear occurred as a saw was passed between the thecal sac and the posterior longitudinal ligament. The median combined estimated blood loss was 6.0 L (IQR, 4.2 to 7.5 L). Sixteen (48%) of the patients underwent intraoperative dural plaque placement, with a median dose of 10 Gy. The median operative time for both stages was 14.2 hours (IQR, 12.2 to 17.6 hours).

Seventeen (52%) of the patients experienced perioperative complications, with 1 death (5.9% of the 17 patients). According to the McDonnell classification, 11 (65%) of the 17 patients experienced a major complication and 6 (35%), a minor complication (Table III). Most of the major complications were pulmonary complications, while cerebrospinal fluid leaks were the most common minor complication (Table IV). One patient died perioperatively. The patient had an L3 to L5 chordoma that abutted the great vessels and was unable to tolerate ligation of the inferior vena cava that was required to safely remove the tumor. The patient developed bowel necrosis postoperatively and died.

Long-Term Complications

Seven (22%) of the patients had complications that occurred within 90 days after discharge, most commonly infection and deep-vein thrombosis. Eight (25%) of the patients had complications occurring > 90 days after discharge, with instrumentation failure (7 patients) being the most common cause. In total, 8 (25%) of the patients experienced instrumentation failure, with a median time to hardware failure of 39 weeks (IQR, 23 to 42 weeks). Fourteen (44%) of the patients required reoperation, with all cases of instrumentation failure requiring

TABLE VII Comparison of Total En Bloc Spondylectomy Studies

Study	Tumor Location	Tumor Type	No. of Included Patients	Study Design*
Boriani et al. ³ (2010)	Cervical, thoracic, lumbar	Primary malignant, solitary metastases	134	R
Amendola et al. ¹⁶ (2014)	Cervical, thoracic, lumbar	Primary malignant, primary benign	103	R
Kawahara et al. ²⁵ (2011)	Lumbar	Primary benign, solitary metastases	10	R
Krepler et al. ²¹ (2002)	Thoracic, lumbar	Primary malignant	7	R
Fourney et al. ²² (2001)	Thoracic, lumbar	Primary malignant, solitary metastases	26	R
Liljenqvist et al. ²³ (2008)	Thoracic, lumbar	Primary malignant, solitary metastases	21	R
Sciubba et al. ²⁸ (2016)	Lumbar	Primary malignant, primary benign	23	R

*R = retrospective.

surgery. Six patients had wound infection that required surgical drainage, and 2 patients underwent resection for local recurrence (Table V).

Oncologic Outcomes

Surgical margins free of cancer cells as confirmed on pathologic evaluation were obtained for 30 (94%) of the patients. Local recurrence was observed in 2 (6%) of the patients. Two (6%) of the patients developed new metastases (Table VI).

Long-Term Outcomes

The median direct clinical follow-up was 72 weeks. Twenty-five (78%) of the patients had normal motor function with at least 6 months of follow-up, and 7 (22%) had preserved motor function with mild weakness. Thirty (94%) of the patients remained ambulatory with the ability to provide self-care (Table VI).

Discussion

Livière et al.⁶ and Stener and Johnsen^{7,19} were the first to describe spondylectomy for spinal tumors in the 1960s and 1970s. In 1994, Tomita et al.¹ and Fidler²⁶ reported on TES, a technique resulting in prolonged survival and reduced recurrence rates compared with intralesional resection¹¹⁻¹⁵.

We describe a staged en bloc spondylectomy employing threadwire saws as well as a cohort of patients who underwent this procedure and the associated safety and outcome profile. We hypothesize that the combination of passing the saws between the thecal sac and the vertebral body in the first, posterior stage and sawing in an anterolateral direction in the second, anterior stage protects major vessels and the spinal cord from injury. Our findings support this hypothesis, as we observed only 1 case of dural injury secondary to the passage of the saws.

This study had limitations. First, there may have been selection bias, as most patients had normal preoperative neu-

rologic status and high performance status. Including patients with worse preoperative scores might have resulted in worse outcomes. Therefore, we are not able to state that this technique is indicated for all patients with spinal tumors. Furthermore, we are not able to compare our technique with a single-stage posterior approach or a staged approach performed without the use of threadwire saws. Finally, our retrospective review of complications likely underestimated the overall complication rate.

Staged resection of spinal tumors decreases morbidity and the duration of stay in the ICU (intensive care unit) compared with single-stage approaches⁴⁰. Furthermore, a 2-stage procedure allows for dissection of the tumor from anterior structures under direct visualization, reducing the risk of damage to major vessels anterior to the vertebral column^{32,41}. Although our approach can be performed in a single day—we have performed some in this fashion that are not included in this study—the rationale for separating the stages by 1 to 7 days is to allow the patient to recover from the systemic inflammatory response initiated by the first stage⁴⁰.

As described by Tomita and colleagues^{31,42}, we use multifilament diamond saws that cut bone and may reduce the risk of tumor cell contamination during vertebral osteotomy³². The saws are placed anterior to the vertebral body, as described by Tomita et al.¹. The key difference from their approach is that we pass 1 end of each saw between the thecal sac and the posterior longitudinal ligament (Fig. 4). This enables us to saw in an anterolateral direction in the second stage, potentially reducing the risk of vascular complications by allowing for visualization of the great vessels.

We performed this technique in 33 patients with primary spinal tumors and solitary metastases of the thoracic and lumbar spine. There have been multiple reports of TES in the thoracic spine^{1,2,7,20,26}. Because of the challenging nature of lumbar tumors, there are relatively few studies of TES in the lumbar spine^{24,25,28}.

TABLE VII (continued)

TES Approach	No. (%) of Patients with Perioperative Complications	No. (%) of Patients with Hardware Failure	Percentage with Negative Margins	No. (%) of Patients with Tumor Recurrence
Combined anterior-posterior, single-stage posterior	47 (35%)	10 (7%)	—	35 (26%)
Combined anterior-posterior, single-stage posterior	43 (42%)	10 (9.7%)	82%	34 (33%)
Combined anterior-posterior	6 (60%)	2 (20%)	100%	0 (0%)
Single-stage posterior	3 (43%)	2 (29%)	100%	0 (0%)
Combined anterior-posterior	12 (46%)	1 (3.8%)	—	2 (7.7%)
Combined anterior-posterior, single-stage posterior	—	1 (4.8%)	71%	2 (9.5%)
2-stage posterior-anterior	15 (65%)	9 (39%)	74%	2 (8.7%)

TES in the lumbar spine requires a 2-stage approach; the diseased vertebral body cannot be safely removed from a single-stage posterior approach because of the lack of space between bridging lumbar roots^{24,28,43}. Our series included 20 lumbar tumors and 1 tumor spanning the thoracolumbar junction.

The morbidity of TES is considerable because of the manipulation of neurovascular structures required in these procedures⁵. Our perioperative complication rate (52%) is in line with rates in the literature (35% to 65%) (Table VII). Infection and deep-vein thrombosis were the most common complications encountered within 90 days after discharge. Impaired wound-healing with subsequent infection is a known complication of TES in patients with a history of radiation therapy⁴⁴. Our instrumentation-failure rate (25%) is consistent with published reports of failure of varying TES approaches (3.8% to 39%)^{28,45} (Table VII). Diminished tissue vitality from preoperative radiation and intraoperative vascular dissection make successful long-term instrumentation challenging in these patients⁴⁵.

The most important aspect of TES is its superior oncologic outcomes. In line with other studies, we achieved a high negative margin rate (94%) and low tumor recurrence rate (6.3%). The 2 patients with positive surgical margins had tumor extension into the epidural space, with a positive margin on the anterior aspect of the dura. All patients had preserved motor function and 94% of the patients remained ambulatory with the ability to provide self-care with at least 6 months of follow-up.

In conclusion, our 2-stage modified en bloc spondylectomy employing threadwire saws is a complex but effective technique for the resection of primary spinal tumors and solitary metastases involving the thoracolumbar spine in selected patients. ■

Akash A. Shah, BS¹
Nuno R. Paulino Pereira, MD¹
Frank X. Pedlow, MD¹
John C. Wain, MD²
Sam S. Yoon, MD³
Francis J. Hornicek, MD, PhD¹
Joseph H. Schwab, MD, MS¹

¹Department of Orthopaedic Surgery, Massachusetts General Hospital, Boston, Massachusetts

²Division of Thoracic Surgery, St. Elizabeth's Medical Center, Brighton, Massachusetts

³Department of Surgery, Memorial Sloan Kettering Cancer Center, New York, NY

E-mail address for J.H. Schwab: jhschwab@mgh.harvard.edu

ORCID iD for J.H. Schwab: [0000-0003-1156-3864](https://orcid.org/0000-0003-1156-3864)

References

- Tomita K, Kawahara N, Baba H, Tsuchiya H, Nagata S, Toribatake Y. Total en bloc spondylectomy for solitary spinal metastases. *Int Orthop*. 1994 Oct;18(5):291-8.
- Tomita K, Kawahara N, Baba H, Tsuchiya H, Fujita T, Toribatake Y. Total en bloc spondylectomy. A new surgical technique for primary malignant vertebral tumors. *Spine (Phila Pa 1976)*. 1997 Feb 1;22(3):324-33.
- Boriani S, Bandiera S, Donthineni R, Amendola L, Cappuccio M, De Iure F, Gasbarrini A. Morbidity of en bloc resections in the spine. *Eur Spine J*. 2010 Feb;19(2):231-41. Epub 2009 Aug 19.
- Weinstein JN, McLain RF. Primary tumors of the spine. *Spine (Phila Pa 1976)*. 1987 Nov;12(9):843-51.
- Sundaresan N, DiGiacinto GV, Krol G, Hughes JEO. Spondylectomy for malignant tumors of the spine. *J Clin Oncol*. 1989 Oct;7(10):1485-91.
- Lièvre JA, Darcy M, Pradat P, Camus JP, Bénichou C, Attali P, Joublin M. Giant cell tumor of the lumbar spine; total spondylectomy in 2 states. *Rev Rhum Mal Osteoartic*. 1968 Mar;35(3):125-30.

7. Stener B. Total spondylectomy in chondrosarcoma arising from the seventh thoracic vertebra. *J Bone Joint Surg Br.* 1971 May;53(2):288-95.
8. Roy-Camille R, Saillant G, Bissserie M, Judet TH, Hautefort E, Mamoudy P. Total excision of thoracic vertebrae. *Rev Chir Orthop Reparatrice Appar Mot.* 1981;67(3):421-30.
9. Roy-Camille R, Mazel C, Saillant G, Lapresle P. Treatment of malignant tumors of the spine with posterior instrumentation. In: Sundaresan N, Schmidek HH, Schiller AL, Rosenthal D, editors. *Tumors of the spine.* Philadelphia: Saunders; 1990. p 473-87.
10. Tomita K, Toribatake Y, Kawahara N, Ohnari H, Kose H. Total en bloc spondylectomy and circumspinal decompression for solitary spinal metastasis. *Paraplegia.* 1994 Jan;32(1):36-46.
11. Boriani S, Chevalley F, Weinstein JN, Biagini R, Campanacci L, De lure F, Piccoli P. Chordoma of the spine above the sacrum. Treatment and outcome in 21 cases. *Spine (Phila Pa 1976).* 1996 Jul 1;21(13):1569-77.
12. Boriani S, De lure F, Bandiera S, Campanacci L, Biagini R, Di Fiore M, Bandello L, Picci P, Bacchini P. Chondrosarcoma of the mobile spine: report on 22 cases. *Spine (Phila Pa 1976).* 2000 Apr 1;25(7):804-12.
13. Melcher J, Disch AC, Khodadadyan-Klostermann C, Tohtz S, Smolny M, Stöckle U, Haas NP, Schaser KD. Primary malignant bone tumors and solitary metastases of the thoracolumbar spine: results by management with total en bloc spondylectomy. *Eur Spine J.* 2007 Aug;16(8):1193-202. Epub 2007 Jan 25.
14. Schwab J, Gasbarrini A, Bandiera S, Boriani L, Amendola L, Picci P, Ferrari S, Boriani S. Osteosarcoma of the mobile spine. *Spine (Phila Pa 1976).* 2012 Mar 15;37(6):E381-6.
15. Kato S, Murakami H, Demura S, Yoshioka K, Kawahara N, Tomita K, Tsuchiya H. More than 10-year follow-up after total en bloc spondylectomy for spinal tumors. *Ann Surg Oncol.* 2014 Apr;21(4):1330-6. Epub 2013 Oct 23.
16. Amendola L, Cappuccio M, De lure F, Bandiera S, Gasbarrini A, Boriani S. En bloc resections for primary spinal tumors in 20 years of experience: effectiveness and safety. *Spine J.* 2014 Nov 1;14(11):2608-17. Epub 2014 Feb 20.
17. Boriani S, Bandiera S, Biagini R, Bacchini P, Boriani L, Cappuccio M, Chevalley F, Gasbarrini A, Picci P, Weinstein JN. Chordoma of the mobile spine: fifty years of experience. *Spine (Phila Pa 1976).* 2006 Feb 15;31(4):493-503.
18. Schoenfeld AJ, Hornicek FJ, Pedlow FX, Kobayashi W, Raskin KA, Springfield D, DeLaney TF, Nielsen GP, Mankin HJ, Schwab JH. Chondrosarcoma of the mobile spine: a review of 21 cases treated at a single center. *Spine (Phila Pa 1976).* 2012 Jan 15;37(2):119-26.
19. Stener B, Johnsen OE. Complete removal of three vertebrae for giant-cell tumour. *J Bone Joint Surg Br.* 1971 May;53(2):278-87.
20. Stener B. Complete removal of vertebrae for extirpation of tumors. A 20-year experience. *Clin Orthop Relat Res.* 1989 Aug;245:72-82.
21. Krepler P, Windhager R, Bretschneider W, Toma CD, Kotz R. Total vertebrectomy for primary malignant tumours of the spine. *J Bone Joint Surg Br.* 2002 Jul;84(5):712-5.
22. Fournay DR, Abi-Said D, Rhines LD, Walsh GL, Lang FF, McCutcheon IE, Gokaslan ZL. Simultaneous anterior-posterior approach to the thoracic and lumbar spine for the radical resection of tumors followed by reconstruction and stabilization. *J Neurosurg.* 2001 Apr;94(2)(Suppl):232-44.
23. Liljenqvist U, Lerner T, Halm H, Buerger H, Gosheger G, Winkelmann W. En bloc spondylectomy in malignant tumors of the spine. *Eur Spine J.* 2008 Apr;17(4):600-9. Epub 2008 Jan 24.
24. Abe E, Sato K, Tazawa H, Murai H, Okada K, Shimada Y, Morita H. Total spondylectomy for primary tumor of the thoracolumbar spine. *Spinal Cord.* 2000 Mar;38(3):146-52.
25. Kawahara N, Tomita K, Murakami H, Demura S, Yoshioka K, Kato S. Total en bloc spondylectomy of the lower lumbar spine: a surgical techniques of combined posterior-anterior approach. *Spine (Phila Pa 1976).* 2011 Jan 1;36(1):74-82.
26. Fidler MW. Radical resection of vertebral body tumours. A surgical technique used in ten cases. *J Bone Joint Surg Br.* 1994 Sep;76(5):765-72.
27. Kawahara N, Tomita K, Murakami H, Demura S. Total en bloc spondylectomy for spinal tumors: surgical techniques and related basic background. *Orthop Clin North Am.* 2009 Jan;40(1):47-63. vi.
28. Sciubba DM, De la Garza Ramos R, Goodwin CR, Xu R, Bydon A, Witham TF, Gokaslan ZL, Wolinsky JP. Total en bloc spondylectomy for locally aggressive and primary malignant tumors of the lumbar spine. *Eur Spine J.* 2016 Dec;25(12):4080-7. Epub 2016 Jun 4.
29. Luzzati AD, Shah S, Gagliano F, Perrucchini G, Scotto G, Alloisio M. Multilevel en bloc spondylectomy for tumors of the thoracic and lumbar spine is challenging but rewarding. *Clin Orthop Relat Res.* 2015 Mar;473(3):858-67.
30. Clarke MJ, Hsu W, Suk I, McCarthy E, Black JH 3rd, Sciubba DM, Bydon A, Yassari R, Witham TF, Gokaslan ZL, Wolinsky JP. Three-level en bloc spondylectomy for chordoma. *Neurosurgery.* 2011 Jun;68(2)(Suppl Operative):325-33; discussion 333.
31. Tomita K, Kawahara N. The threadwire saw: a new device for cutting bone. *J Bone Joint Surg Am.* 1996 Dec;78(12):1915-7.
32. Cloyd JM, Acosta FL Jr, Polley MY, Ames CP. En bloc resection for primary and metastatic tumors of the spine: a systematic review of the literature. *Neurosurgery.* 2010 Aug;67(2):435-44; discussion 444-5.
33. Yamazaki T, McLoughlin GS, Patel S, Rhines LD, Fournay DR. Feasibility and safety of en bloc resection for primary spine tumors: a systematic review by the Spine Oncology Study Group. *Spine (Phila Pa 1976).* 2009 Oct 15;34(22)(Suppl):S31-8.
34. Kneisl JS, Rosenberg AE, Anderson PM, Antonescu CR, Bruland OS, Cooper K, Horvai AE, Holt GE, O'Sullivan B, Patel SR, Rose PS. Bone. In: Amin MB, Edge SB, Greene FL, Byrd DR, Brookland RK, Washington MK, Gershenwald JE, Compton CC, Hess KR, Sullivan DC, Jessup JM, Brierley JD, Gaspar LE, Schilsky RL, Balch CM, Winchester DP, Asare EA, Madera M, Gress DM, Meyer LR, editors. *AJCC cancer staging manual.* 8th ed. Cham: Springer International; 2017. p 471-86.
35. Kirshblum SC, Burns SP, Biering-Sorensen F, Donovan W, Graves DE, Jha A, Johansen M, Jones L, Krassioukov A, Mulcahey MJ, Schmidt-Read M, Waring W. International standards for neurological classification of spinal cord injury (revised 2011). *J Spinal Cord Med.* 2011 Nov;34(6):535-46.
36. Oken MM, Creech RH, Tormey DC, Horton J, Davis TE, McFadden ET, Carbone PP. Toxicity and response criteria of the Eastern Cooperative Oncology Group. *Am J Clin Oncol.* 1982 Dec;5(6):649-55.
37. McDonnell MF, Glassman SD, Dimar JR 2nd, Puno RM, Johnson JR. Perioperative complications of anterior procedures on the spine. *J Bone Joint Surg Am.* 1996 Jun;78(6):839-47.
38. Colman MW, Hornicek FJ, Schwab JH. Spinal cord blood supply and its surgical implications. *J Am Acad Orthop Surg.* 2015 Oct;23(10):581-91. Epub 2015 Sep 16.
39. DeLaney TF, Liebsch NJ, Pedlow FX, Adams J, Dean S, Yeap BY, McManus P, Rosenberg AE, Nielsen GP, Harmon DC, Spiro IJ, Raskin KA, Suit HD, Yoon SS, Hornicek FJ. Phase II study of high-dose photon/proton radiotherapy in the management of spine sarcomas. *Int J Radiat Oncol Biol Phys.* 2009 Jul 1;74(3):732-9. Epub 2008 Dec 25.
40. Brown MJ, Kor DJ, Curry TB, Warner MA, Rodrigues ES, Rose SH, Dekutoski MB, Moriarty JP, Long KH, Rose PS. Sacral tumor resection: the effect of surgical staging on patient outcomes, resource management, and hospital cost. *Spine (Phila Pa 1976).* 2011 Sep 1;36(19):1570-8.
41. Kawahara N, Tomita K, Baba H, Toribatake Y, Fujita T, Mizuno K, Tanaka S. Cadaveric vascular anatomy for total en bloc spondylectomy in malignant vertebral tumors. *Spine (Phila Pa 1976).* 1996 Jun 15;21(12):1401-7.
42. Tomita K, Kawahara N, Murakami H, Demura S. Total en bloc spondylectomy for spinal tumors: improvement of the technique and its associated basic background. *J Orthop Sci.* 2006 Jan;11(1):3-12.
43. Stener B. Technique of complete spondylectomy in the thoracic and lumbar spine. In: Sundaresan N, Schmidek HH, Schiller AL, Rosenthal D, editors. *Tumors of the spine.* Philadelphia: Saunders; 1990. p 432-7.
44. Yokogawa N, Murakami H, Demura S, Kato S, Yoshioka K, Hayashi H, Ishii T, Igarashi T, Fang X, Tsuchiya H. Perioperative complications of total en bloc spondylectomy: adverse effects of preoperative irradiation. *PLoS One.* 2014 Jun 3;9(6):e98797.
45. Matsumoto M, Watanabe K, Tsuji T, Ishii K, Nakamura M, Chiba K, Toyama Y. Late instrumentation failure after total en bloc spondylectomy. *J Neurosurg Spine.* 2011 Sep;15(3):320-7. Epub 2011 Jun 3.